

Metastatic Mammary Lobular Carcinoma Presenting with Ileal Obstruction: A Case Report

ABSTRACT

Aim: The aim of this article is to present a rare case of ileal metastasis from lobular mammary carcinoma. **Background:** Breast cancer has the highest incidence among women and is prone to develop distant metastasis. Metastasis to the gastrointestinal (GI) tract is rare and occurs more frequently in invasive lobular carcinoma. Patients may be asymptomatic or present with variable vague symptoms that may be mistakenly attributed to side effects of chemotherapy or other benign GI diseases. **Case Description:** This case report describes a 78-year-old Indian female patient with bilateral lobular mammary cancer who presented with ileal obstruction. **Conclusion:** Metastatic lobular mammary carcinoma has a wide range of clinical presentations. Adequate procedures should be performed promptly to obtain histological diagnosis. The possibility of intestinal involvement by metastasis should be considered in a known case of breast carcinoma with acute abdominal symptoms. **Clinical Significance:** Increased awareness of bowel metastasis secondary to breast cancer and a thorough understanding of the clinical and histological features are fundamental to avoid delay in diagnosis and management.

Key words: Breast cancer, Ileal obstruction, Intestinal metastasis

INTRODUCTION

Breast cancer is the most common cancer in females and metastasizes frequently to lung, pleura, skin, bone, soft tissues, liver, and brain. The gastrointestinal (GI) tract is an uncommonly reported site of metastatic disease.^[1] However, tumor metastasis from the breast to the small intestine has been increasingly reported since 1964, acquiring researchers' attention because of its obscure clinical presentation and difficulty in diagnosis.^[2]

CASE REPORT

A 78-year-old Indian female presented with acute intestinal obstruction, constipation, and obstipation. Endoscopy revealed superficial erosions and a tight stricture in terminal ileum. Computed tomography scan of the thorax, abdomen, and pelvis revealed bilateral breast lesions suggestive of neoplastic etiology. Circumferential thickening of the distal ileum was radiologically suspicious for a stricture. Biopsy from the right breast lesion was diagnosed as invasive lobular carcinoma (ILC) and was confirmed by immunohistochemistry (IHC). To relieve the ileal obstruction, she underwent resection of ileal stricture with anastomosis. On gross examination, the resected segment of ileum measured 13 cm in length. Serosa showed puckering. No adhesions or exudate were seen. A 2-cm long annular stricture was identified with luminal narrowing. Mucosa at the stricture was flat; no ulcer or growth was identified.

Shrutika Jadhav¹, Gautmi Badkar², Girish Muzumdar²

¹Department of Pathology, Bombay Hospital Institute of Medical Sciences, Mumbai, Maharashtra, India, ²Department of Histopathology, Bombay Hospital Institute of Medical Sciences, Mumbai, Maharashtra, India

Corresponding Author:

Dr. Shrutika Jadhav, Department of Pathology, Bombay Hospital Institute of Medical Sciences, Mumbai, Maharashtra, India
E-mail: jadhav.shrutika25@gmail.com

Microscopic examination from the stricture showed transmural infiltration by neoplastic cells extending into the subserosal fat. Tumor cells were arranged in sheets and having focal Indian file pattern. Cells were medium sized with round uniform nuclei. Mitotic activity was conspicuous. Mucosa was intact [Figure 1a and b]. On IHC [Figure 1c-g], the tumor cells expressed GATA3, estrogen receptor (ER), progesterone receptor (PR), and p120, indicating a metastasis from breast primary. Further tumor cells were negative for E-cadherin which indicated metastatic lobular carcinoma in ileal stricture. Tumor cells did not express LCA, CD20, CK20, and Her 2 neu.

DISCUSSION

Isolated small intestinal obstruction secondary to tumor metastasis is rare. Lobular breast cancer and melanoma are

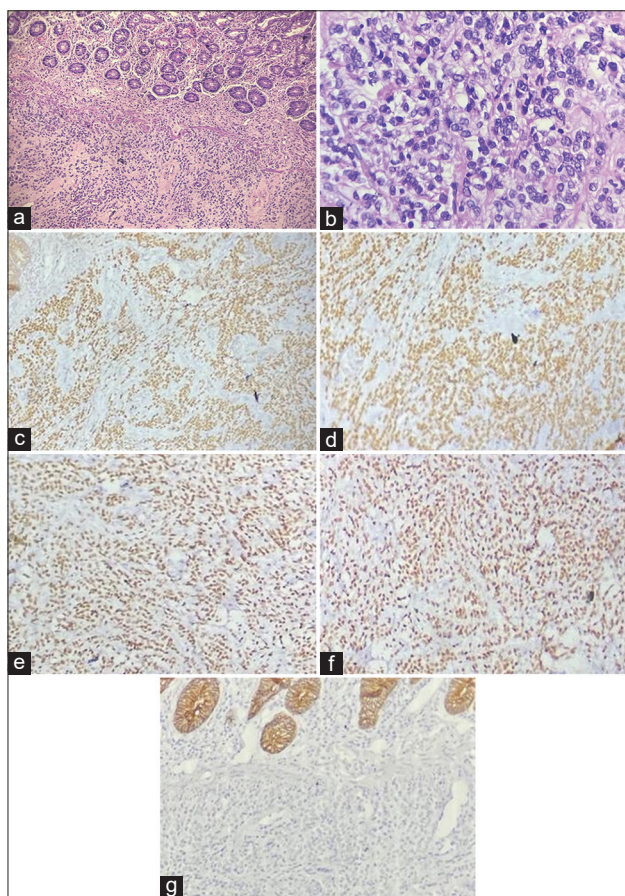


Figure 1: Representative histopathological results of small intestine metastasis. Small intestine metastasis was found to be diffuse infiltrating the submucosal muscularis propria. (a) (H&E staining, $\times 200$). (b) (H&E staining, $\times 400$), Immunohistochemical staining expressed GATA3 (c), estrogen receptor (d), and progesterone receptor (e). Besides, p120 catenin was cytoplasmically positive (f). While E cadherin (g) was not expressed. (Immunohistochemical staining, $\times 200$)

the most frequent primary malignancies that metastasize to and obstruct the small intestine.^[3] According to a study done by Idelevich *et al.*, among the 36 patients who presented with intestinal obstruction, 17 had metastases secondary to breast cancer, with lobular cancer being the only pathological type in all cases.^[4]

The most common site of GI involvement from breast cancer in literature was the stomach. Colon involvement is quite common, while small intestine involvement is very rare and diagnosed very late, frequently at autopsy.^[5]

With regard to clinical manifestations, symptoms may range from non-specific complaints to acute GI symptoms such as GI bleeding, intestinal obstruction, and perforation symptoms such as abdominal pain, distention, and abdominal mass; nausea; and vomiting, among which abdominal pain is especially common.^[6,7] In the current case, the patient presented initially with GI symptoms that made her seek

medical attention without taking into account the breast lesion. The time interval between primary breast cancer and GI involvement may range from synchronous presentation to as long as 30 years after adequate management, but the reverse is also true, with the GI manifestations preceding the diagnosis of the breast cancer.^[8]

Differentiation of breast metastasis from other GI primaries can be difficult and IHC is crucial to establishing accurate diagnosis. Commonly used markers include ERs and PRs, CK7, and CK20. A CK7-/CK20+ profile favors a large bowel primary, while CK7+/CK20- favors a metastasis.^[9] In our case, IHC results of tumor cells from the intestinal stricture expressed ER, PR, GATA3, and p120 as well as the CK20 combination, all of which supported the conclusion of metastasis from breast cancer.

ILC is characterized by a mutation in the tumor suppressor gene CDH1, which encodes E-cadherin.^[10] E-cadherin plays a role in regulating cell adhesion and migration; therefore, loss of E-cadherin expression results in loss of cell adhesion within the tumor and may promote metastasis.^[11] ILC also is more likely to metastasize to the contralateral breast, retroperitoneum, peritoneum, GI tract, and genitourinary tract.

CONCLUSION

Metastatic ILC has a wide range of clinical presentations. Small bowel metastasis from ILC is rare. Patients presenting with GI symptoms and having a suspicious breast lump and metastases of ILC to the GI tract must be excluded from the study.

CLINICAL SIGNIFICANCE

Since small bowel metastasis of tumors from the breast is difficult to recognize and is often diagnosed when acute intestinal symptoms manifest,^[3] clinicians should consider small bowel metastasis as a cause of intestinal obstruction when treating patients with lobular breast cancer, despite no clinically apparent manifestation of malignancy. Endoscopy, radiological examinations, and histological evaluation are necessary to differentiate primary GI carcinoma from metastatic disease as well as inflammatory causes of stricture.

REFERENCES

1. Taal BG, Peterse H, Boot H. Ictal presentation, endoscopic features, and treatment of gastric metastases from breast carcinoma. *Cancer* 2000;89:2214-21.
2. Graham WP 3rd. Gastro-intestinal metastases from carcinoma of the breast. *Ann Surg* 1964;159:477-80.
3. Budzyński P, Pędziwiatr M, Kenig J, Lasek A, Winiarski M, Major P, *et al.* Gastrointestinal obstruction in patients previously treated for malignancies. *Pol Przegl Chir* 2016;88:93-8.
4. Idelevich E, Kashtan H, Mavor E, Brenner B. Small bowel obstruction caused by secondary tumors. *Surg Oncol* 2006;

- 15:29-32.
5. Ambroggi M, Stroppa EM, Mordenti P, Biasini C, Zangrandi A, Michieletti E, *et al.* Metastatic breast cancer to the gastrointestinal tract: Report of five cases and review of the literature. *Int J Breast Cancer* 2012;2012:439023.
 6. Zheng Y, Zhao Q. Metastatic tumors in the small bowel: A report of 3 cases. *Chin J Clin Oncol* 1990;17:78-9.
 7. Lee MH, Zaheer A, Voltaggio L, Johnson PT, Fishman EK. Clinical time course and CT detection of metastatic disease to the small bowel. *Abdom Radiol (NY)*. 2019;44:2104-10.
 8. Arrangoiz R, Papavasiliou P, Dushkin H, Frama JM. Case report and literature review: Metastatic lobular carcinoma of the breast an unusual presentation. *Int J Surg Case Rep* 2011;2:301-5.
 9. Cervi G, Vettoretto N, Vinco A, Cervi E, Villanacci V, Grigolato P, *et al.* Rectal localization of metastatic lobular breast cancer: Report of a case. *Dis Colon Rectum* 2001;44:453-5.
 10. Dossus L, Benusiglio PR. Lobular breast cancer: incidence and genetic and non- genetic risk factors. *Breast Cancer Res* 2015;17:37.
 11. Christgen M, Steinemann D, Kühnle E, Länger F, Gluz O, Harbeck N, *et al.* Lobular breast cancer: Clinical, molecular and morphological characteristics. *Pathol Res Pract* 2016;212:583-97.

How to cite this article: Jadhav S, Badkar G, Muzumdar G. Metastatic Mammary Lobular Carcinoma Presenting with Ileal Obstruction: A Case Report. *Bombay Hosp J* 2024;66(1):12-14.

Source of support: Nil, **Conflicts of interest:** None

This work is licensed under a Creative Commons Attribution 4.0 International License. The images or other third party material in this article are included in the article's Creative Commons license, unless indicated otherwise in the credit line; if the material is not included under the Creative Commons license, users will need to obtain permission from the license holder to reproduce the material. To view a copy of this license, visit <http://creativecommons.org/licenses/by/4.0/> © Jadhav S, Badkar G, Muzumdar G. 2024.