

Lobar Pneumonia with Profound Neutropenia (Absolute Neutrophil Count 12 only) Caused by SARS COVID 2 Infection in adult Immunocompetent Patient who has Taken Both COVID-19 Vaccine

ABSTRACT

Neutropenia is a known but rare hematological complication of COVID-19 infection in immunocompetent patients. There is sparse literature on neutropenia in patients with COVID-19, except for a few case reports. We encountered a similar case in an intensive care unit that presented with lobar pneumonia with profound neutropenia (Neutrophil count 30) who had no comorbidity and taken both COVID-19 vaccines as per recommendation. The patient was admitted to an isolated negative pressure room with antiviral, antifungal, and antibiotics along with low molecular heparin started. Patient deteriorated and required high flow nasal cannula oxygen support with steroid supplementation. Thus, we treated successfully, a patient with SARS COV 2 infection with lobar pneumonia complicated with profound neutropenia with no co-morbidity which improved with Granulocyte colony stimulating factors to normal level=13.

Key words: Antiviral drugs, Granulocyte colony stimulating factors, Profound neutropenia, SARS COV 2 infection

INTRODUCTION

Severe acute respiratory syndrome coronavirus 2 (SARS CoV 2) is a strain of coronavirus that causes the acute respiratory illness responsible for the COVID-19 pandemic. The virus is airborne and primarily spreads between people through close contact and via aerosols and respiratory droplets. It can spread via while talking breathing, or otherwise exhaling, as well as those produced from coughs and sneezes. Lymphopenia is known in viral infection but Neutropenia is rare hematological finding in immunocompetent person. Neutropenia respond to anti-viral drugs, vitamin supplementation and granulocyte stimulating factors.

CASE REPORT

A 56-years-old female presented with a complaint of fever, right-sided chest pain and cough with purulent expectoration for 4 days. Fever was high grade and associated with chills, which relived by taking tablet paracetamol. Chest pain was right sided, sharp in nature and aggravated on deep inspiration and coughing (pleuritic). Patient was having cough which was productive, initially associated whitish expectoration later become yellowish expectoration. She had no past history of Tuberculosis or Bronchial asthma or any obstructive airway disease. Patient had taken both COVID-19 vaccine in past. Patient is a known case of hypothyroidism taking tablet Thyronorm 50 mcg once daily.

On examination, she was conscious, oriented with temperature of 98 F, pulse was 116/min regular in rhythm. Blood pressure 110/70 mm of Hg, respiratory rate was 30/min, SpO₂ 98% on room air. Systemic examinations revealed crepitation over the base of the right lungs in infra-

Nitin Rathod, Amishi Rathod, Sandeep Duvvada,
Harshkumar Boda

Department of Internal Medicine, Nanavati Max Multispeciality Hospital, Mumbai, Maharashtra, India

Corresponding Author:

Amishi Rathod, Department of Internal Medicine, Nanavati Max Multispeciality Hospital, Mumbai, Maharashtra, India.
E-mail: amishirathod@hotmail.com

scapular area along with increased vocal resonance. Rest of the systemic examination revealed no significant abnormalities. Her investigations are as follows. Complete blood count (CBC) revealed severe leukopenia with low neutrophil count (Neutropenia), Dengue panel and malarial parasites were negative. Urine routine was normal. Blood and sputum culture showed no growth. Chest X-ray was done which showed soft tissue opacity in Right lower lobe pneumonia (Consolidation). 2 D echo was reported normal. Nasal swab Respiratory Biofire assay was done which was positive for SARS COVID-2 and reconfirmed with nasal swab reverse transcription polymerase chain reaction (RT PCR). Patient was shifted to isolation room in view of infectious disease and severe neutropenia. Patient presented with tachypnea and drop in oxygen saturation for which oxygen support with high flow nasal cannula started.

Her serial CBC, C-reactive protein, and procalcitonin monitoring revealing neutropenia and subsequent recovery.

D-dimer on 8/3/24 — 4.47 mg/mL.

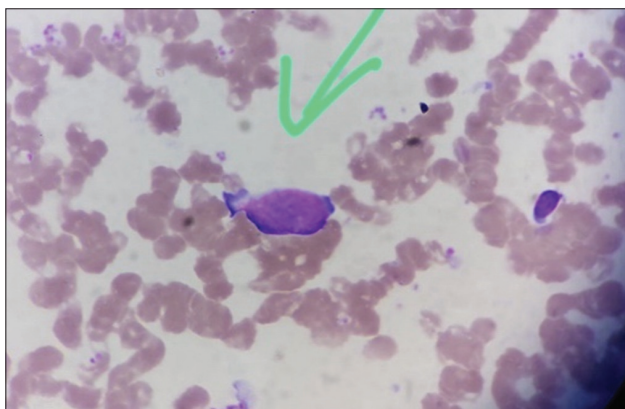


Figure 1: Green Arrow indicates BLAST cell seen on bone marrow examination

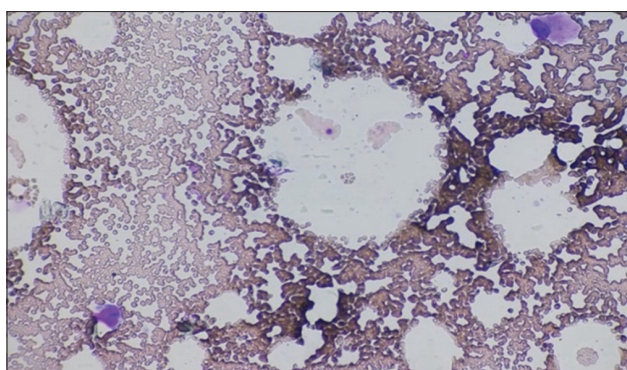


Figure 2: This image demonstrates hypobulbated megakaryocyte seen on bone marrow examination

After diagnosing SARS COV-2 infection, patient was started on Inj. Remdesivir 200 mg intravenous stat followed by 100/ per day along with injection Enoxaparin 0.6 mL S.C once a day. Tab fluconazole and Tab acyclovir were started and intravenous antibiotics continued prophylactically in view of severe neutropenia.

Inj Methylprednisolone 40 mg intravenous was started which was gradually tapered off because of severe cough and breathlessness. Patient was started on granulocyte colony stimulating factors (GCSF) 300 micrograms per day for 5 days. Further Patient had episode of Atrial fibrillation (may be related to hypoxia or myocarditis) which was controlled by amiodarone, Initially, intravenous bolus followed by infusion and gradually shifted to oral forms. Serum Protein electrophoresis was done which showed reduction in total protein and albumin levels and mildly increased alpha 1 globulin levels. Immunoglobulin A 206 g/dL, Immunoglobulin G 760 g/dL, Immunoglobulin M 36 g/dL borderline low (40–230 g/dL). It was not suggestive of myeloma.

Her Bone Marrow aspiration with bone biopsy done in view of persistent neutropenia to r/o myelodysplastic syndrome. Bone marrow aspiration showed mildly hypercellular marrow showing 8% blast cells and mild dysplasia in erythroid and megakaryocytic series with myeloid suppression (Figures 1 and 2).

Table 1: Serial CBC monitoring revealing neutropenia and subsequent recovery

Date	Hemoglobin (g/dL)	TLC (cells/mL) (N/L/M/E/B)	Platelets
February 27, 24	13	469 (12/424/25/8/0)	224k
February 28, 24	13.4	340 (10.2/324/3.74/2.04)	219k
February 29, 24	12.9	300 (12.9/268.5/17.1/1.5)	238k
March 1, 24	12.6	360 (35.64/225.7/93.24/1.8/3.6)	272k
March 2, 24	10.8	860 (210.7/445.5/202.1)	315k
March 3, 24	10.9	6720 (3494.4/1612.8/403.2)	283k
March 4, 24	11.9	26380 (17410.8/1319/1319)	330k
March 5, 24	11.4	22290 (18322.38/2541.1/1426.56)	314k
March 6, 24	11.8	11790 (9821.07/1120/848.88)	371k
March 7, 24	11.5	9360 (8143.2/926.6/290.16)	459k
March 9, 24	11.1	5460 (4307.94/961/191.1)	571k
March 10, 24	11.2	6400 (4473.6/1369.1/556.8)	592k

CBC: Complete blood count

Table 2: Her CRP monitoring

Date	CRP
February 27, 24	238.75 mg/dL
February 29, 24	399 mg/dL
March 2, 24	167 mg/dL

CRP: C-reactive protein

Table 3: Her serial PCT monitoring

Date	PCT
February 28, 24	4.89 ng/mL
March 1, 24	3.30 ng/mL
March 7, 24	0.5 ng/mL

PCT: Procalcitonin

High-resolution computed tomography scan of CHEST revealed area of lobar consolidation in right lower lobe with few patent bronchi along with slight pleural effusion (Figures 3 and 4).

Patient started improving clinically and oxygen saturation improved with nasal prong support. Gradually oxygen support was tapered off and removed. Patient white blood cell count along with Neutrophil count improved. Patient had no further episodes of fever or breathlessness hence injection. meropenem, acyclovir, fluconazole was stopped and started de-escalated antibiotics. Repeat COVID-19 RT PCR was done which was negative after 7 days and shifted to medical ward. In the ward, her sputum culture grew *stentrophomonas maltophilia* which was sensitive to levofloxacin. After appropriate treatment, patient improved and discharged subsequently (Tables 1-3).

DISCUSSION

From previous experience and available literature that an early or delayed severe neutropenia could be found during severe

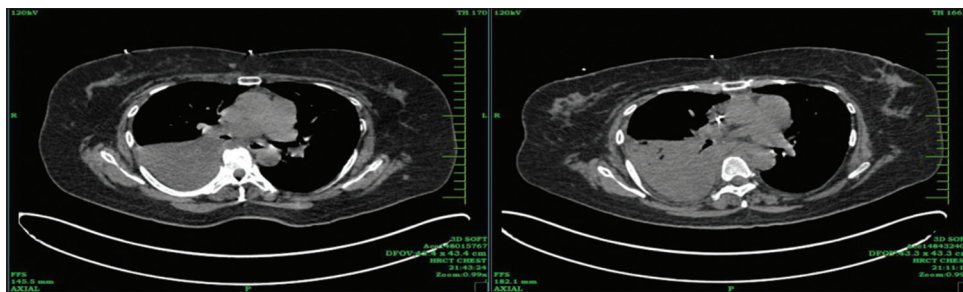


Figure 3: High-resolution computed tomography CHEST performed on admission demonstrating consolidation in lower zone of right lung

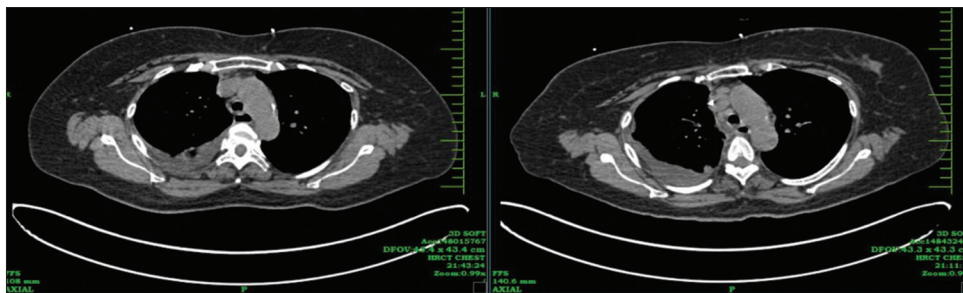


Figure 4: Repeat high-resolution computed tomography CHEST performed after 5 days demonstrating good clearance of consolidation in right lower zone following treatment

COVID-19 infection^[1] and could be a result of transient bone marrow suppression by significant inflammatory response during viral infection. Leukopenia occurs in 17–33% of patients, but it is primarily due to lymphopenia.^[2] The definition of neutropenia is usually defined as an absolute neutrophil count (ANC) <1000 cells/mL, severe neutropenia as an ANC <500 cells/mL, or an ANC that is expected to decrease to <500 cells/mL over the next 48 h, and profound neutropenia as an ANC <100 cells/mL. It could be the possibility that like certain other viral infection or other hematological condition like myelodysplastic syndrome, it is one of the hematological manifestations that is yet under-reported as most cases are asymptomatic and may go unnoticed. Hematologists should be involved in the management of such cases and any concurrent illnesses causing neutropenia should be ruled out. Strict asepsis should be maintained with covering with antifungal, antibiotic and antiviral drugs along with GCSF should be started.^[3]

CONCLUSION

In ongoing pandemic, febrile neutropenic patients should be precisely evaluated for COVID-19 disease.^[4] It should be remembered that there may not be typical signs and symptoms and laboratory findings of COVID-19 disease. One should remember that no vaccine is 100% protective. People can get COVID-19 even after vaccination. However,

the vaccination may help to protect them from developing severe disease.^[5]

REFERENCES

1. Mank VM, Mank J, Ogle J, Roberts J. Delayed, transient and self-resolving neutropenia following COVID-19 pneumonia. *BMJ Case Rep* 2021;14:e242596.
2. Bouslama B, Pierret C, Khelifaoui F, Bellanné-Chantelot C, Donadieu J, Héritier S. Post-COVID-19 severe neutropenia. *Pediatr Blood Cancer* 2021;68:e28866.
3. Nawar T, Morjaria S, Kaltsas A, Patel D, Perez-Johnston R, Daniyan AF, *et al.* Granulocyte-colony stimulating factor in COVID-19: Is it stimulating more than just the bone marrow? *Am J Hematol* 2020;95:E210-3
4. Spencer HC, Wurzbürger R. COVID-19 presenting as neutropenic fever. *Ann Hematol* 2020;99:1939-40.
5. Amanat F, Krammer F. SARS-CoV-2 vaccines: Status report. *Immunity* 2020;52:583-9.

How to cite this article: Rathod N, Rathod A, Duvvada S, Boda H. Lobar Pneumonia with Profound Neutropenia (Absolute Neutrophil Count 12 only) Caused by SARS COVID 2 Infection in adult Immunocompetent Patient who has Taken Both COVID-19 Vaccine. *Bombay Hosp J* 2024;66(1):19-21.

Source of support: Nil, **Conflicts of interest:** None

This work is licensed under a Creative Commons Attribution 4.0 International License. The images or other third party material in this article are included in the article's Creative Commons license, unless indicated otherwise in the credit line; if the material is not included under the Creative Commons license, users will need to obtain permission from the license holder to reproduce the material. To view a copy of this license, visit <http://creativecommons.org/licenses/by/4.0/> © Rathod N, Rathod A, Duvvada S, Boda H. 2024.