

# Internal Carotid Artery Dissection Presenting as Isolated Hypoglossal Nerve Palsy – A Case Report

## ABSTRACT

As compared to other cranial nerves, hypoglossal nerve palsy is rare; and is often associated with other lower cranial nerve palsies. The most common causes of hypoglossal nerve palsies are tumors followed by trauma, stroke, surgery, infection, and multiple sclerosis. We report a case of a 55-year-old male presenting with dysphagia, dysarthria, and difficult mastication. He was diagnosed to have isolated hypoglossal nerve palsy secondary to compression by internal carotid artery dissection (ICAD). He was treated conservatively with antiplatelets and showed improvement on a 6-month follow-up. ICAD is a dangerous entity with possible endangering complications and hence recognition of it is critical for appropriate treatment and prevention of possible complications. ICAD should be considered in differential diagnosis for isolated hypoglossal nerve palsy.

**Key words:** Carotid dissection, Hypoglossal nerve palsy, Treatment of dissection

## INTRODUCTION

Hypoglossal nerve palsy is most seen post head-and-neck surgeries, trauma, infective, and secondary to compressive etiologies such as tumors such as chordoma, lymphoma, and glomus.<sup>[1]</sup> Usually, it is associated with other lower cranial nerve involvement and isolated hypoglossal nerve palsy is very rare. Hypoglossal nerve palsy presents with more signs rather than symptoms, but when it does, it can present as dysphagia, dysarthria, difficulty in mastication, and other symptoms associated with other lower cranial nerve involvement.

Spontaneous dissection of carotid or vertebral arteries is one of the common causes of ischemic strokes in the young- and middle-aged population.<sup>[2]</sup> Lower cranial nerve palsies are frequently associated with internal carotid artery dissection (ICAD), particularly the hypoglossal nerve. We present an unusual case of isolated hypoglossal nerve palsy as a presentation of ICAD.

## CASE PRESENTATION

A 55-year-old male presented with complaints of dysphagia for 1 week and difficulty in mastication (moving the bolus of food in mouth) for 3–4 days. He also complained of slurring of speech which made few of his pronunciation difficult to understand. He had no history of trauma. Neurological examination revealed tongue deviation to the left on protrusion and dysarthria suggesting left hypoglossal nerve palsy. No other neurological findings were noted. Blood pressure on admission was 140/80 mmHg.

No acute infarct was noted on diffusion-weighted magnetic resonance images (MRI) to explain the hypoglossal nerve palsy. Magnetic resonance angiography (MRA) demonstrated

Jharna Mahajan<sup>1</sup>, Rakesh Singh<sup>1</sup>, Neekesh Baweja<sup>1</sup>, Riddhi Patel<sup>2</sup>, Satish Khadilkar<sup>1</sup>

<sup>1</sup>Department of Neurology, Bombay Hospital Institute of Medical Sciences, Mumbai, Maharashtra, India, <sup>2</sup>Fellow, Neuro intervention, Breach Candy Hospital, Mumbai, Maharashtra, India

### Corresponding Author:

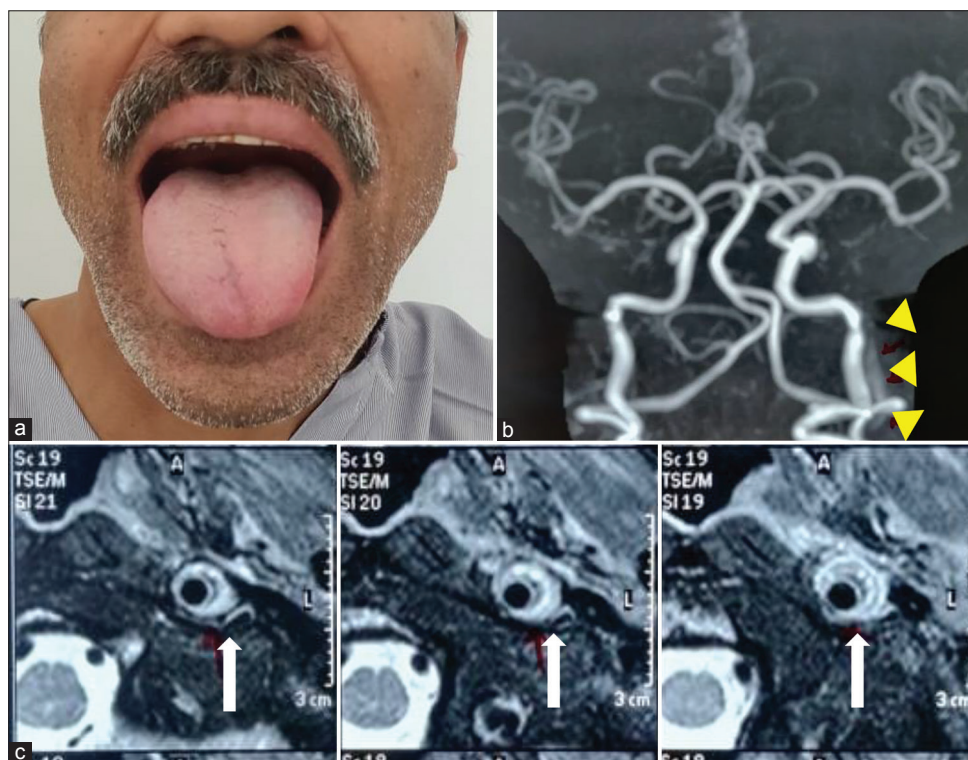Rakesh K. Singh, Department of Neurology, Bombay Hospital Institute of Medical Sciences, Mumbai, Maharashtra, India. Phone: +91-9223347374. E-mail: drrakeshn@gmail.com

left ICAD with a false lumen. T1 fat-saturated sequences images demonstrated a false lumen of ICAD that compressed the outgoing hypoglossal nerve tube with hyperintensity in the hypoglossal canal. These findings suggested that the false lumen of ICAD was causing compression of the hypoglossal nerve hence causing 12<sup>th</sup> nerve palsy [Figure 1a-c].

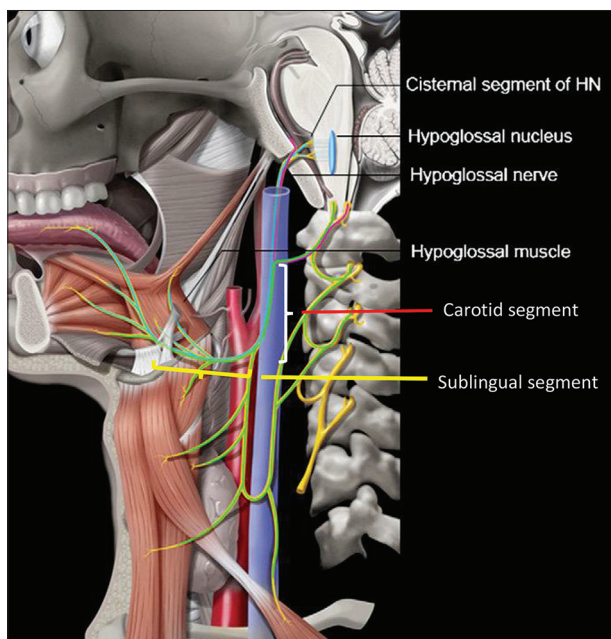
The patient was admitted and was started on tablet aspirin 150 mg/day to prevent thromboembolism from the dissected portion of the artery. On follow-up after 6 weeks, tongue deviation persisted with atrophy on the left hemitongue, but the patient had significant improvement in the tongue function and dysarthria had completely resolved with some residual difficulty in mastication.

## DISCUSSION

Spontaneous ICAD is a relatively rare disease with the annual incidence of carotid dissection being 2.5–3/100,000.<sup>[2,3]</sup> The extracranial segments of the carotid as well as vertebral arteries



**Figure 1:** (a) Demonstration of deviation of the tongue toward the left. (b) Magnetic resonance angiogram of the left distal cervical internal carotid artery (ICA) is dilated and shows an elongated hyperintense signal on MR angiography within the wall of the artery likely hematoma/thrombosed false lumen (yellow arrows) (c) Proton density axial (PD TRA sequence) showing dilated ICA and shows eccentric hyperintense signal likely thrombosed false lumen compressing the hypointense true lumen and resulting in compression of the hypoglossal nerve coursing along its posterior wall (white arrows)



**Figure 2:** Course and different segments of the hypoglossal nerve

are much more prone to dissections than their intracranial segments due to the free mobility of the extracranial segment. The intimal tear permits blood under arterial pressure to penetrate the artery wall, leading to the formation of an intramural hematoma, often referred to as the false lumen. The majority of ICAD cases arises spontaneously and can be attributed to minor subclinical traumas such as sneezing, coughing, vomiting, or neck manipulation. Additional etiologies include arterial hypertension, fibromuscular dysplasia, autosomal dominant polycystic kidney disease, ICA redundancy, infectious diseases, or connective tissue disorders.<sup>[4]</sup>

The main symptoms of ICAD can be divided into – (a) local manifestations such as acute onset unilateral neck pain, unilateral facial and orbital pain, occipital headache, and cranial nerve palsies, (b) Ischemic manifestations present as neurological deficits, blurring of vision, or blindness.<sup>[5]</sup> MRA or CT angiography is the most important investigation for diagnosis of the ICAD. Proton density axial imaging and fat-saturated MRI sequences reveal a crescent-shaped T1 high signal within the vessel wall, indicating a mural hematoma, accompanied by luminal narrowing.

The hypoglossal nerve serves as the motor nerve for controlling the intrinsic muscles of the tongue and palate, excluding the palatoglossus. The inferolateral precentral gyrus cortical center, responsible for tongue movement, sends fibers to the contralateral medullary hypoglossal nucleus. From there, the medullary segment of CNXII travels anterolaterally, exiting the preolivary sulcus. This segment traverses the pre-medullary cistern posterolateral to the vertebral artery, making it prone to vascular or neoplastic lesions.

The extracranial course comprises the carotid segment and the final sublingual segment. The carotid segment extends from the hypoglossal canal through the carotid space at the nasopharynx level, passing between the internal jugular vein and the internal carotid artery. At this juncture, the hypoglossal nerve is susceptible to compression due to ICA pseudoaneurysm or dissection [Figure 2].

The sublingual segment is susceptible to floor-of-mouth neoplasms, infections, and inflammation.

Lower cranial neuropathies as a presentation of ICAD are rare with various case reports described in the literature. Sturzenegger *et al.*, in 1993, analyzed 36 cases with ICAD and multiple cranial nerve palsies and they concluded that 6% of patients present with isolated hypoglossal nerve palsy.<sup>[6]</sup> Murakami *et al.*, have summarized 29 cases of ICAD with lower cranial nerve palsy.<sup>[7]</sup> The most common nerve to be involved was the hypoglossal nerve (11 of 37 patients – 29.7%), followed by IX, X, and XI nerves.<sup>[8]</sup> To date, approximately 40 cases of ICAD presenting with lower cranial nerve palsy have been reported in the literature.

The most common treatment for ICAD is anticoagulant or antiplatelet therapy to prevent thromboembolic complications of dissection.<sup>[9]</sup> In patients with no benefit from antiplatelets, carotid artery stenting is preferred. An analysis of 201 ICAD patients who underwent CAS revealed a surgical success rate of 99.1%. During the perioperative period, the incidence of major cardiovascular events was 4%.<sup>[10]</sup>

## CONCLUSIONS

Although hypoglossal nerve palsy is an infrequent occurrence in ICAD, it can present as the sole clinical indicator. Therefore, maintaining a high index of suspicion for ICAD is crucial to expedite prompt and suitable therapy. Radiologists

should be knowledgeable about the imaging characteristics of hypoglossal nerve palsy to ensure timely and appropriate treatment for ICAD.

## REFERENCES

1. Stino AM, Smith BE, Temkit M, Reddy SN. Hypoglossal nerve palsy: 245 cases. *Muscle Nerve* 2016;54:1050-4.
2. Schievink WI. Spontaneous dissection of the carotid and vertebral arteries. *N Engl J Med* 2001;344:898-906.
3. Lee VH, Brown RD, Mandrekar JN, Mokri B. Incidence and outcome of cervical artery dissection: A population-based study. *Neurology* 2006;67:1809-12.
4. Campos-Herrera CR, Scaff M, Yamamoto FI, Conforto AB. Spontaneous cervical artery dissection: An update on clinical and diagnostic aspects. *Arq Neuropsiquiatr* 2008;66:922-7.
5. Jurkiewicz MT, Stein JM, Learned KO, Nasrallah IM, Loevner LA. Hypoglossal nerve palsy due to carotid artery dissection: An uncommon presentation of a common problem. *Neuroradiol J* 2019;32:123-6.
6. Sturzenegger M, Huber P, Sturzenegger M. Cranial nerve palsies in spontaneous carotid artery dissection. *J Neurol Neurosurg Psychiatry* 1993;56:1191-9.
7. Murakami Y, Oda K, Konno Y, Matsumoto Y, Saito K. Successfully treated with endovascular therapy against lower cranial nerve paresis caused by spontaneous dissection of the cervical internal carotid artery: A case report. *J Neuroendovasc Ther* 2016;10:30-5.
8. Kidoguchi T, Fukui I, Abe H, Mori K, Tamase A, Yamashita R, *et al.* Carotid artery stenting for spontaneous internal carotid artery dissection presenting with hypoglossal nerve palsy: A case report. *Surg Neurol Int* 2022;13:225.
9. Markus HS, Levi C, King A, Madigan J, Norris J. Antiplatelet therapy vs anticoagulation therapy in cervical artery dissection: The cervical artery dissection in stroke study (cadiss) randomized clinical trial final results. *JAMA Neurol* 2019;76:657-64.
10. Zeleňák K, Zeleňáková J, DeRiggo J, Kurča E, Kantorová E, Poláček H. Treatment of cervical internal carotid artery spontaneous dissection with pseudoaneurysm and unilateral lower cranial nerves palsy by two silk flow diverters. *Cardiovasc Intervent Radiol* 2013;36:1147-50.

**How to cite this article:** Mahajan J, Singh R, Baweja N, Patel R, Khadilkar S. Internal Carotid Artery Dissection Presenting as Isolated Hypoglossal Nerve Palsy – A Case Report. *Bombay Hosp J* 2023;65(4):19-21.

**Source of support:** Nil, **Conflicts of interest:** None

This work is licensed under a Creative Commons Attribution 4.0 International License. The images or other third party material in this article are included in the article's Creative Commons license, unless indicated otherwise in the credit line; if the material is not included under the Creative Commons license, users will need to obtain permission from the license holder to reproduce the material. To view a copy of this license, visit <http://creativecommons.org/licenses/by/4.0/> © Mahajan J, Singh R, Baweja N, Patel R, Khadilkar S. 2024.