

Colloid Cysts of the Third Ventricle: A Review of Literature with Personal Experience

ABSTRACT

Colloid cyst of the third ventricle is the most common benign lesion of the anterior third ventricle. Although considered congenital, its tissue of origin and pathogenesis is a matter of debate. It was first discovered in 1858, with the diagnosis typically being established at autopsy, due to the non-specific nature of symptoms and the risk of producing sudden death. Several studies have reported on its natural history to establish guidelines to identify candidates for management. Magnetic resonance imaging is the imaging modality of choice, however, computed tomography scan may demonstrate the lesion as well. Although benign in nature, the deep location of the lesion increases the risk of significant operative morbidity. Microsurgery remains the gold standard of surgical management. Endoscopic cyst excision, with all its newer advances, is rapidly gaining popularity being minimally invasive.

Key words: Cerebral ventricular tumor, Colloid cyst, Endoscopy, Hydrocephalus, Microsurgery, Third ventricle

INTRODUCTION

Colloid cyst is a cystic brain lesion comprising 0.5–1% of all intracranial neoplasms. It contains gelatinous material enclosed within a membrane of epithelial tissue. Wallman first reported on a colloid cyst in 1858.^[1] Its paraphyseal origin was first described by Sjövall in 1909, who termed it a paraphyseal cyst of the third ventricle.^[2] Its developmental origin is unclear, although the presence of ciliated epithelium and mucinous contents may point toward an endodermal source.

The strategic nature of its location is likely to cause obstruction of the cerebrospinal fluid (CSF) pathway at the foramen of Monro. A majority of earlier cases were discovered only at the time of autopsy, due to the non-specificity of symptoms and its propensity to cause sudden death.

We briefly review the existing theories about its embryopathogenesis, natural history, and management based on existing English literature. We have also described our own personal experience with the surgical case series with changes in management over the past 20 years.

EMBRYOLOGY AND PATHOPHYSIOLOGY

The colloid cyst is considered to be a vestige of an embryonic structure called the paraphysis. The paraphysis is a glandular structure found in some lower vertebrates, arising from the roof of the third ventricle just posterior to the foramen of Monro.^[3] In the human embryo, it appears around the 75th day of gestation and normally disappears shortly thereafter. In some individuals, remnants of the gland persist and slowly enlarge, presumably by retention of products of the secreting epithelial cells.

Chandrashekhkar Eknath Deopujari, Aniruddha Abhay Bhagwat, Vikram S Karmarkar

Department of Neurosurgery, Bombay Hospital Institute of Medical Sciences, Mumbai, Maharashtra, India

Corresponding Author:

Chandrashekhkar Eknath Deopujari, Department of Neurosurgery, Bombay Hospital Institute of Medical Sciences, Mumbai, Maharashtra, India.
E-mail: d.chandrashekhkar11@gmail.com

The lesion grows downward, and to a varying extent, upward and forward. In the course of its growth, it is enfolded by layers of the tela, hence, it is sometimes thought of as a cyst of the choroid plexus.

The cyst grows at the site of foramen of Monro, leading to obstructive hydrocephalus, usually in an episodic manner, sometimes related to the patient's position. The severity of hydrocephalus depends on the rate of growth of the cyst. Often, slowly growing cysts present in the older population with features similar to normal pressure hydrocephalus (NPH). The mechanism of sudden death may be attributable to acute obstructive hydrocephalus producing brain herniation, or hypothalamic compression producing neurogenic stunned myocardium and cardiac failure.^[4]

NATURAL HISTORY

This is a subject of great controversy and debate. Various studies have tried to find answers to this vexing question for

efficacious management. A study by Pollock *et al.* indicated that the rate of progression of asymptomatic cases is 0%, 0%, and 8% at 2, 5, and 10 years, respectively.^[5] About 5–15% of such patients are likely to require operative intervention within 5 years of diagnosis.^[6]

Symptomatic patients have a much higher chance of neurological deterioration – as much as 34% according to some studies.^[7] The risk of sudden death in such patients cannot be accurately predicted, however, numerous case reports are available in world literature.^[8–10] Colloid cyst is the most likely of all benign tumors of the third ventricle to precipitate sudden death of the patient.^[11]

CLINICAL FEATURES

Clinical presentation depends on four variables – cyst size, imaging appearance of cyst contents, ventricle size, and age of the patient. Symptoms may be typical of an anterior third ventricular lesion with episodes of headache and various features of raised intracranial pressure (ICP) without any specific localizing features, namely, vertigo, memory disturbances, cognitive decline, and occasionally with restriction of eye movements.^[3] This is additionally characterized by intermittency or positional manifestation of headache and vomiting. According to early reports by Slade *et al.*, a vast majority of cases in the pre-imaging era were discovered to have a colloid cyst only at autopsy, carried out for the investigation of sudden death. This is classically caused due to acute obstructive hydrocephalus because of blockage of foramen of Monro by ball valve mechanism as well as direct compression of hypothalamus.

Younger patients are more likely to present with headache, with papilledema, while older patients are more likely to present with chronic hydrocephalic symptoms of insidious onset, namely, memory disturbances, gait abnormalities and urinary incontinence, and mimicking NPH.

Rare presentations include rapid progression of headache followed by neurological deterioration due to spontaneous hemorrhage into the cyst^[12] or local mass effect due to a giant colloid cyst, that is, size >3 cm.^[13]

IMAGING

Computed tomography (CT) scan was the first definitive diagnostic modality for colloid cysts. These are slightly hyperdense lesions at the foramen of Monro which often have associated biventricular hydrocephalus^[14] [Figure 1a]. Occasionally, they may be missed because of their isodense nature and very rarely may they show contrast enhancement^[15] [Figure 1b].

Magnetic resonance imaging (MRI) is the current modality of choice for definitive diagnosis. Typical findings on MRI include:

- Homogenous or heterogeneous lesion in the region of foramen of Monro. Cyst intensity may depend on the nature of the contents, but is usually hyperintense on T1 [Figure 1c] and hyperintense [Figure 1d] to hypointense [Figure 1e] on T2-weighted images. Degree of T2 hypointensity may correspond with the viscosity or consistency of the cyst contents, although this is not always so. It may dictate the choice of surgery, as aspiration of solid contents is difficult by stereotactic or endoscopic method. Some cysts may show a central T2 hypointensity

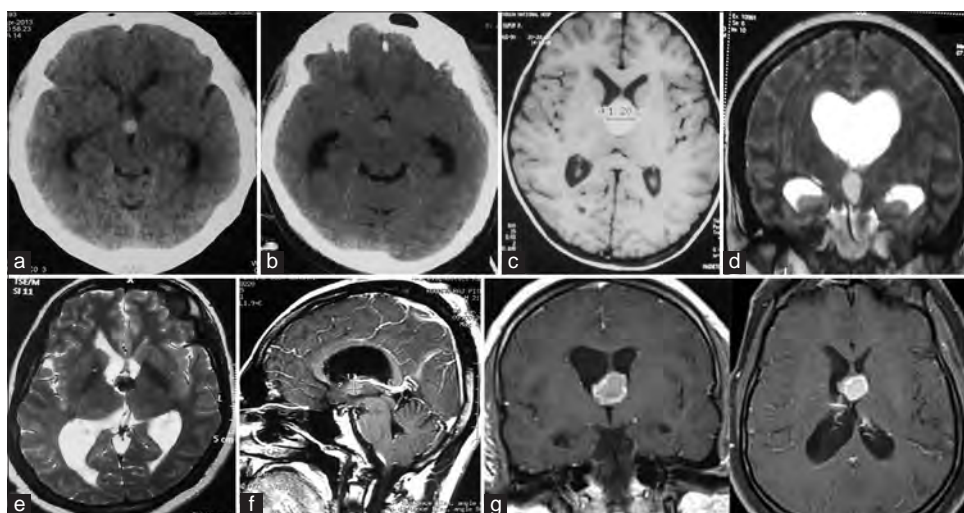


Figure 1: Normal imaging appearance of a colloid cyst. (a) Axial view of plain computed tomography (CT) showing hyperdense colloid cyst. (b) Plain CT scan axial view showing an isodense colloid cyst, which may produce a diagnostic dilemma. (c) T1-weighted axial view of magnetic resonance imaging (MRI) showing a mildly hyperintense colloid cyst. (d) T2-weighted coronal view of MRI showing a mildly hyperintense colloid cyst. (e) T2-weighted axial view of MRI showing a hypointense colloid cyst. (f) Contrast-enhanced T1-weighted sagittal view of MRI showing a non-enhancing colloid cyst. (g) Contrast-enhanced T1-weighted coronal and axial views of MRI showing mild peripheral enhancement of a hyperintense colloid cyst

surrounded by hyperintense rim, while some may show uniform T2 hyperintensity

- The lesion is non-enhancing on contrast sequences [Figure 1f], but may rarely show a mildly enhancing rim [Figure 1g]
- Cyst size can be accurately measured, for clinical decision-making and follow-up comparisons
- Displacement of fornices and septum pellucidum can be well seen
- Enlarged lateral ventricles with periventricular ooze (hyperintense on T2 and FLAIR and hypointense on T1). Dilation of foramen of Monro and its relation to the cyst can be properly assessed.

Differential diagnoses seen in our experience include –

- Subependymal giant cell astrocytoma
- Chordoid glioma of third ventricle
- Aneurysms of the anterior communicating artery or at the bifurcation of the basilar artery
- Pilocytic astrocytoma [Figure 2a]
- Neurocysticercosis [Figure 2b]
- Primary central nervous system lymphoma [Figure 2c].

MANAGEMENT OF COLLOID CYSTS OF THE 3rd VENTRICLE

Patients with asymptomatic cysts, especially those which grow very slowly and are not associated with hydrocephalus, are likely to indefinitely remain in an asymptomatic state.^[16] They should be under observation and should undergo follow-up imaging. A protocol based on the cyst size, ventricular dilatation, and symptoms is given in Table 1.

Beaumont *et al.* have recently developed a colloid cyst risk score (CCRS) to identify and stratify symptomatic patients,^[17] based on such criteria as age, location in the third ventricle (risk zone), size of the cyst (more than 7 mm), FLAIR hyperintensity, and the presence of headache. The CCRS has been rated to be highly reliable in this context, although the strength of agreement varies among its various criteria.^[18,19] The score has been demonstrated to have very high reliability for criteria such as age and presence of FLAIR hyperintensity, moderate reliability for size criterion, and low reliability for risk zone and presence of headache.^[19]

Medical management does not have much of a role in symptomatic patients. Steroids, Diamox, and osmotic decongestive therapy may be used in emergency till patient can reach the surgical facility.

SURGICAL APPROACHES

Walter Dandy performed the first surgical excision of a colloid cyst in 1921,^[20] through a transcortical transventricular approach. Since then, various microsurgical and minimally invasive approaches including endoscopic techniques gradually evolved.

Table 1: Proposed protocol for the management of 3rd ventricular colloid cysts

Size	Symptoms	Hydrocephalus	Optimal management
<7 mm	Asymptomatic	Absent	Observation
≥7 mm	Any	Any	Resection
Any	Any	Present	Resection

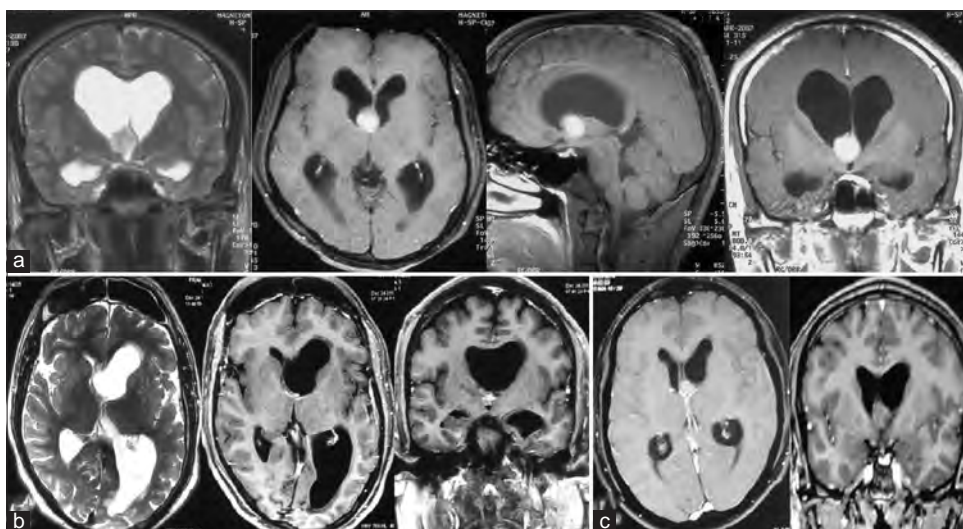


Figure 2: Radiological differential diagnoses. (a) Pilocytic astrocytoma – T2-weighted coronal image and contrast-enhanced T1-weighted axial, sagittal, and coronal images showing a homogeneously enhancing lesion at the foramen of Monro. (b) Neurocysticercosis – T2-weighted axial image and contrast-enhanced T1-weighted axial and coronal images showing a minimally enhancing solid-cystic lesion at the left foramen of Monro, producing asymmetric lateral ventriculomegaly. (c) Lymphoma – contrast-enhanced T1-weighted axial and coronal views showing mildly contrast enhancing lesion, suggestive of a lymphoma

Lara *et al.* performed freehand aspiration of a colloid cyst in 1975.^[21] Bosch *et al.* performed the first stereotactic aspiration of a colloid cyst in 1978.^[22] This technique may be considered if complete aspiration of cyst contents is possible, in the opinion of some authors.^[23] However, since follow-up studies show a significant rate of recurrence, the technique is no longer favored.^[23,24] Powell *et al.*, in 1983, first reported on the use of ventricular endoscopy in establishing the diagnosis of a colloid cyst in cases where they appeared isodense on CT scan, in the pre-MRI days. They further performed therapeutic cyst aspiration endoscopically in such cases.^[15] Minimally invasive stereotactic microsurgical transcortical approach was described by Kondziolka and Lunsford in 1996.^[25]

In the past, bilateral ventricular shunt placement or unilateral shunt with septostomy was considered to be a safe modality for management of colloid cysts, because of the memory and cognitive outcomes of cyst resection surgery were considered to be unacceptably high. However, once it was proved that memory function was mainly linked to the fornix damage and that microsurgical as well as endoscopic

techniques were able to protect them effectively, direct surgery has become the first choice of treatment.^[26] Shunting may be practiced even today, in high-risk cases. Rarely, some patients may require shunts postoperatively in case of long-standing hydrocephalus and advanced age. However, it must be understood that shunting does not treat the underlying cause, and may hamper future attempts at definitive surgery due to chinked ventricles.^[27]

MICROSURGICAL RESECTION

We can approach colloid cysts through microsurgical transcortical [Figure 3a-c] or endoscopic as well as transcallosal approaches. The main concern during transcortical microscopic or endoscopic approaches is the neurodeficit produced by white matter tract disruption, namely, to the superior longitudinal fasciculus I and II. MRI diffusion tensor imaging may be used to obtain three-dimensional images of tracts, which may be integrated with neuronavigation systems in planning the

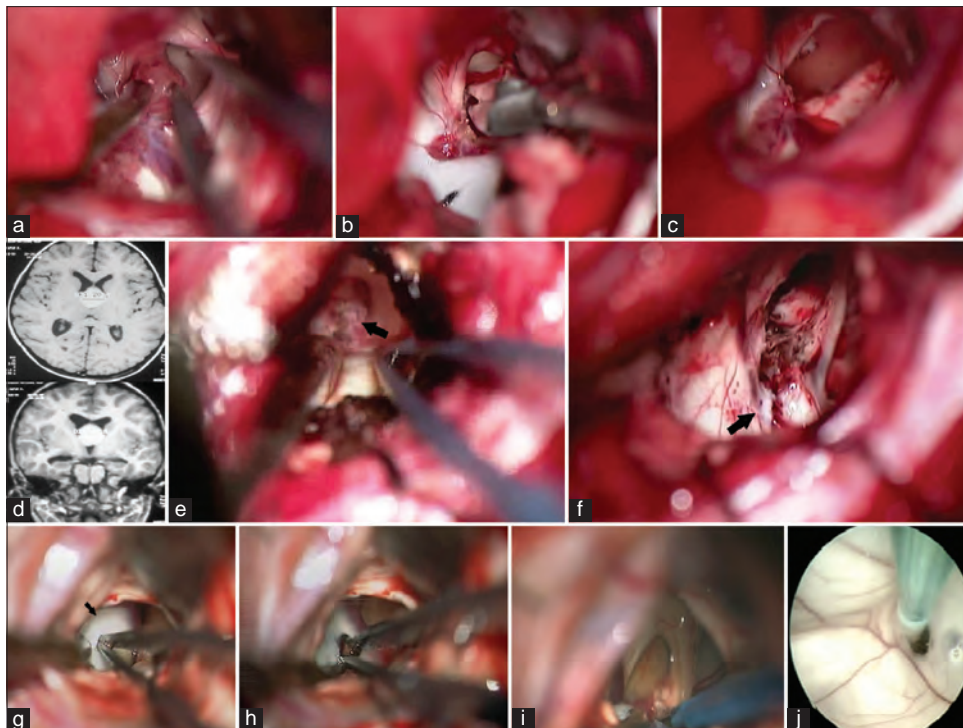


Figure 3: Microsurgical procedures: (a) Transcortical approach – right superior frontal sulcus approach to enter the right frontal horn. Colloid cyst within the foramen of Monro. Choroid plexus and thalamostriate vein are visible. (b) Attachment of the cyst is being divided as close as possible to the roof of third ventricle, including some part of the attached choroid plexus. (c) Appearance of operative bed after excision of the cyst. (d) Intraoperative maneuvers – widening of FOM – magnetic resonance imaging showing large colloid cyst, with relatively small foramen of Monro. (e) Intraoperative view showing the cyst (black arrow) filling the foramen of Monro and extending posteriorly. (f) Intraoperative widening of the foramen of Monro was performed posteriorly up to the confluence of the thalamostriate and septal veins. Operative bed post-cyst excision shows this confluence (black arrow). (g) Septostomy – intraoperative photograph of the right transcortical approach showing the septum pellucidum (black arrow) ballooning into the field of view and obscuring the floor of the lateral ventricle and foramen of Monro. (h) Septostomy immediately deflates it. Tip of forceps seen in the septostomy defect. (i) Septum becomes lax and gets retracted. Foramen of Monro with colloid cyst becomes readily visible. (j) Endoscopic septostomy procedure, with the tip of Fogarty catheter seen in the opening

surgical trajectory. The bone flap for craniotomy is usually just in front of the coronal suture off the midline and entry point is in middle frontal gyrus. Several techniques have been devised for minimization of white matter tract dissection, such as the use of syringes, tubular retractors, and silicone trocars for corticotomy.^[28,29] The authors commonly use a saline-inflated glove attached to a brain needle, as a tract dilator. A new device called NICO BrainPath® has been designed for the same purpose.

The transcalsal approach is practiced routinely by many surgeons, but is particularly useful when the ventricles are small and the cyst is more posteriorly placed. The craniotomy is pre-coronal with medial limb of the flap on the sagittal sinus. A relatively avascular space between two parasagittal draining veins is chosen to enter the interhemispheric fissure and the cingulate gyri are gently separated to expose at least 1.5 cm anteroposterior length of the corpus callosum. After identifying both the anterior cerebral arteries, an incision is made in the callosum and deepened to enter the lateral ventricle.

All approaches, whether endoscopic or microsurgical, allow us to gain entry into the lateral ventricle (usually right side, else more dilated frontal horn). Passage from here to the

third ventricle usually takes place through a dilated foramen of Monro. Other pathways such as transchoroidal^[30,31] [Figure 4a], subforniceal/suprachoroidal^[32], or subchoroidal may be utilized to achieve entry into the third ventricle, if the cyst is not presenting at the foramen. A small foramen of Monro may also be surgically widened posteriorly [Figure 3d-f] up to the confluence of the anterior septal vein and thalamostriate vein (at which point they form the internal cerebral vein) to facilitate excision.^[33] Pre-operative venography studies may be useful to predict the feasibility of such an approach.

Sometimes, in patients with significant hydrocephalus, entry into one ventricle causes it to suddenly get decompressed, while the contralateral ventricle remains full. This causes the septum to acutely bulge into the operative field, thus obstructing the operative view of the floor of the lateral ventricle and foramen of Monro. A septostomy may then be created to decompress the opposite ventricle and offer good visualization of the foramen and cyst by making the septum lax, thus allowing it to be retracted safely [Figure 3g-j].

Interforniceal approach into the third ventricle is possible through a midline transcalsal pathway [Figure 4b]. It is greatly facilitated by the presence of a cavum septum pellucidum or cavum vergae, and the surgical morbidity associated with

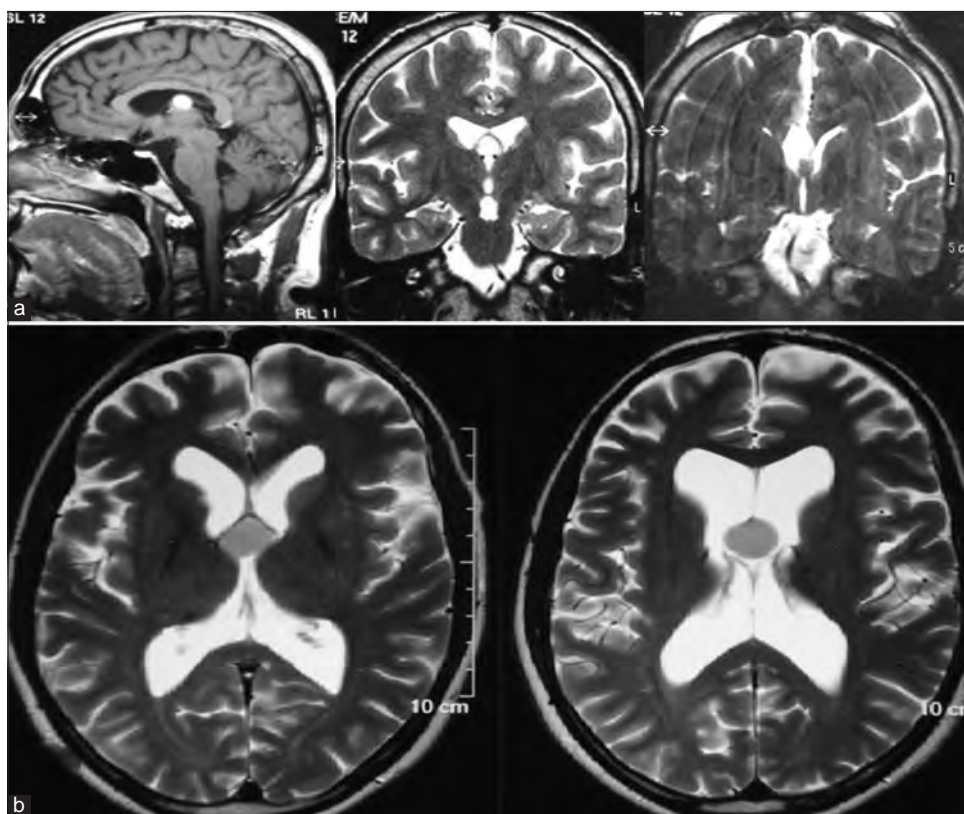


Figure 4: Transcalsal approach to the third ventricle. (a) Transcalsal transchoroidal approach – Plain T1-weighted sagittal, T2-weighted coronal, and post-operative T2-weighted coronal image showing complete excision of posterior third ventricular colloid cyst, which needed to be targeted with a transchoroidal approach. (b) Transseptal-interforniceal approach – midline colloid cyst located within the septal leaflets, optimally targeted with a transseptal-interforniceal approach

forniceal injury is also minimized in these cases. A cavum is more likely to be present in younger patients.

Novel approaches described include translamina terminalis approach^[34] and interhemispheric transgenual approach.^[35] Reexcision of a recurrent cyst or a previously failed excision may need to be dealt with using a different approach using wider corridors and greater exposure.^[36]

COMPLICATIONS OF MICROSURGERY

Memory deficits are a common complication of all approaches, since there is likely to be some degree of injury to the fornix.^[37,38] However, this is much more likely to be transient than permanent.^[34] The transcortical approach is likely to result in a greater incidence of post-operative seizures, subdural effusion, hemiparesis, and cognitive and behavioral deficits. The transcallosal approach may produce callosal syndrome consisting of memory loss, akinetic mutism, and disconnection syndrome.^[39,40] Although venous sacrifice anterior to the coronal suture does not usually matter, it may occasionally cause venous infarction (subcortical). Seizures and subdural effusion are less common with the transcallosal approach. Rarely, one may encounter post-operative hydrocephalus with either of the approaches. A comparison of the results of the two procedures is given in Table 2.

Cauterization at the confluence of veins must be very carefully done, and internal cerebral as well as thalamostriate veins should not be compromised during surgery. The anterior septal vein may be sacrificed if necessary, but should be done some distance away from its confluence with the thalamostriate, as this may produce a propagating thrombus in the vein. The most dreaded complication is deep cerebral venous thrombosis.

NEUROENDOSCOPY

In the pre-MRI era, diagnostic ventricular endoscopy was performed to establish the diagnosis of colloid cyst in cases where the CT appearance was non-diagnostic.^[15] From thereon, the technique has evolved to purely endoscopic complete cyst resection. Endoscopic excision of colloid cyst is known to reduce the extent of dissection, operating time, hospital stay, and infection rate, as compared to transcallosal

microsurgery.^[41-45] Patients are able to return to work earlier as well. The rates of complete excision were lower than microsurgery in the past, and the rates of recurrence were correspondingly higher. However, with the development of new technology, and improvement of endoscopic technique, the results are now comparable.

Procedure

The patient is positioned supine on the operating table, with 20° of neck flexion, on a clamp or horse shoe. The side of ventricular entry is preferably the right, since the lesion is in the midline. It may, however, depend on the lateral extent of the cyst, dimensions of the foramen of Monro, and size of the frontal horn. Neuronavigation is a very useful adjunct to plan a small craniotomy with an optimum trajectory. It is especially useful when endoscopy is to be used in the absence of dilated ventricles.^[46] The optimum entry point is usually around 4.5 cm anterior to the coronal suture and 4cm paramedian.^[47] The authors prefer to use a small 2.5–3 cm craniotomy for entry. After durotomy, the ventricle is tapped with a brain needle, and the corticotomy tract dilated with a saline-inflated glove. Endoscopic port systems, syringes, or tubular retractors may be deployed at this point, to maintain the tract, and prevent injury due to to-and-fro passage of the scope or instruments.^[48,49] The scope is introduced. Unilateral CSF release may cause the septum to bulge against the endoscope, thus impairing vision. This may be tackled by performing a quick septostomy. The ventricular anatomy is carefully studied in the region of the foramen of Monro. Venous anatomy is observed. The cyst is punctured and its contents aspirated. The cyst wall is excised with coagulation of a sufficient length of the choroidal attachment. The fornix and the venous angle are kept in the line of sight the whole time, so as to spare them any injury. After complete excision, hemostasis is confirmed, and the scope withdrawn [Figure 5]. The tract is plugged with a roll of gelfoam.

A two-port technique for excision has been described from AIIMS, New Delhi, with excellent results.^[50] Endoscopic combined transforaminal-transchoroidal surgery is a novel technique that serves to improve the versatility of endoscopy, making it usable even for firmly adherent, sessile cysts, and those located posteriorly along the roof of the third ventricle.^[51]

In case of inability to resect the capsule, the procedure may be converted to microsurgery. This has been shown to improve resection rates.^[52]

Total excision is achieved in more than 60% of cases.^[53] The recurrence rate after excision is very low. Coagulation rather than resection of the cyst wall produces significantly high recurrence rates.^[54] Results are no different between patients with or without ventriculomegaly.^[55] Endoscopic resection of recurrent colloid cysts is equally safe and feasible as primary resection.^[56] Endoscopy produces significantly lower rates of post-operative hydrocephalus.^[57] The less

Table 2: A comparison of the results of transcortical and transcallosal approaches to the excision of colloid cysts

Study (no. of cases)	Transcallosal (%)	Transcortical (%)	Significance
Liu <i>et al.</i> ^[58] (583)			
Seizure	2.9	10.4	Yes
Memory deficit	4.9	5.7	No
Nair <i>et al.</i> ^[40] (297)			
Seizure	3	14	No

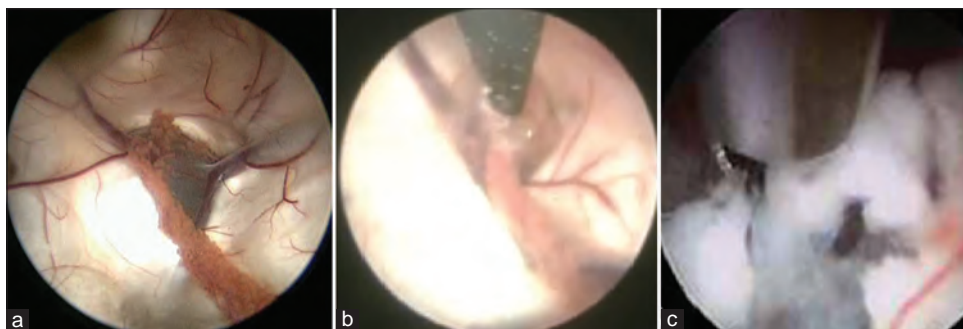


Figure 5: Endoscopic excision of colloid cyst. (a) Endoscopic view of colloid cyst filling the right foramen of Monro. The choroid plexus, anterior septal vein, and thalamostriate vein are seen. (b) Use of bipolar cautery to coagulate the surface of the cyst and choroid plexus. (c) Mucoid proteinaceous content of the cyst is being aspirated

invasive nature leads to decrease in the size of operative site infarct, infections, and seizures.^[57] Some authors propose the use of microsurgical techniques preferably in the pediatric age group, due to the lower incidence of recurrence, which becomes especially significant given the expected longevity of the patient.^[52]

RESULTS OF MICROSURGERY

Microsurgery has been consistently shown to achieve excellent results. A recent meta-analysis comparing microsurgery with neuroendoscopy showed a higher rate of complete cyst excision and lower rates of recurrence and reoperation with microsurgery. However, the surgical morbidity was higher than that of neuroendoscopy.^[58] Incidence of seizures and 30-day post-operative readmission, as well as cost of treatment were higher than endoscopic surgery, as per a study conducted in the USA.^[36,59]

A comparative analysis of the results of microsurgery and neuroendoscopy on the basis of different criteria is given in Table 3.

OUR EXPERIENCE

We have surgically treated a series of 82 cases of colloid cyst through various approaches [Table 4]. We started off with transcallosal approach in the initial cases, but use it currently only if the ventricles are very small. Since the advent of neuroendoscopy in our unit, we have made it our standard practice to make a small parasagittal craniotomy on the more dilated or non-dominant side and enter the lateral ventricle through the middle frontal gyrus. We use either a purely endoscopic or endoscope-assisted approach depending on the degree of dilation of foramen of Monro and consistency of cyst contents.

Transforaminal corridor was tried first in all except two cases where a primary transseptal approach was taken. We have also used the transchoroidal pathway in two cases in

Table 3: A comparison of the results of endoscopic and microsurgical excision of colloid cysts

Study (no. of cases)	Microsurgical (%)	Endoscopic (%)	Significance
Liu et al.^[58] (1278)			
Cyst excision	96.8	58.2	Yes
Mortality	1.4	0.6	No
Sethi et al.^[57] (962)			
Cyst excision	96	78.5	Yes
Complication	18.6	8.7	Yes
Mortality	0.65	1.06	No
Horn et al.^[41] (55)			
Cyst excision	96	75	-
Complication	30	10	-
Grondin et al.^[45] (34)			
Cyst excision	100	96	-
Complication	33	4	-

Table 4: Our experience of surgical management of colloid cysts

Procedure	Number of cases	Remarks
Interhemispheric transcallosal	32	Two recurrent cases
Transcortical microsurgical	22	One recurrent case
Endoscopic (pure)	6	Single-port surgery
Endoscope-assisted microsurgery	22	Further dilation of tract for microsurgery

patients harboring colloid cysts posteriorly and not visible at the foramen of Monro. Transient memory loss lasting 24–72 h, was seen in as many as 50% of the patients, which improved gradually over a period of weeks. In two cases performed through the interforaminal pathway, some memory deficits remained persistent even at 12 months after surgery. All patients were able to return to a functional working status

within 3 months. There was one case of intraoperative death in a patient who presented in an unconscious state. Immediately after tapping the ventricle, brain swelling started, and we could not reach the cyst in this case. Five other patients presented to us in a brain dead condition during the same period, admitted in an unconscious state could not be subjected to surgery as they were beyond salvage.

COLLOID CYSTS IN THE PEDIATRIC POPULATION

Colloid cysts present less commonly in the pediatric population in spite of being congenital lesions. There are a few series published in English literature, such as from the Hospital for Sick Children, Toronto,^[60] and NIMHANS.^[61] In our series, nine out of 82 patients operated on for colloid cysts were below 16 years. The studies show a mean age at presentation of around 13–14 years, and cases usually suffer rapid deterioration. They are thus better candidates for early surgical management. The longer duration of expected survival of the patient stresses the need for a more radical or complete resection of the cyst, so as to avoid recurrence. Microsurgical resection may thus be preferred in such cases.

CONCLUSION

Colloid cyst is the most common mass lesion of the anterior third ventricle. It presents with symptoms of raised ICP, often in an episodic manner. Although there is no consensus on the management protocol, management guidelines such as the CCRS aid the clinician in coming to a decision. In general, asymptomatic cases should be followed up for a minimum of 5 years. Symptomatic cases need early treatment, and patients as well as families must be counseled about its importance. Sudden death is an ever present risk in untreated cases.

Optimum modality of management remains unclear. Microsurgical excision is the gold standard of colloid cyst resection surgery and may be preferred in younger patients, if performed with minimal morbidity. Stereotactic cyst aspiration is safe and effective, but leads to high recurrence rates. Endoscopic resection is gradually advancing and gaining widespread acceptance. It is safe and effective in expert hands.

REFERENCES

1. Wallmann H. Eine colloidcyste im dritten hirnventrikel und ein lipom im plexus chorioides. Arch Pathol Anat Physiol Klin Med 1858;14:385-8.
2. Sjoval E. Über eine ependymcyste embryonalen charakters (paraphyse?) im dritten Hirnventrikel mit tödlichem Ausgang.

Zugleich eine beobachtung wahrer lipochromer veränderungen mit auftreten von halbmondkörperchen. Beitr Pathol Anat 1910;47:248-69.

3. Glazer NM, Hauser H, Slade HW. Paraphyseal or colloid cysts of the third ventricle. Radiology 1956;67:351-8.
4. Turillazzi E, Bello S, Neri M, Riezzo I, Fineschi V. Colloid cyst of the third ventricle, hypothalamus, and heart: A dangerous link for sudden death. Diagn Pathol 2012;7:144.
5. Pollock BE, Huston J. Natural history of asymptomatic colloid cysts of the third ventricle. J Neurosurg 1999;91:364-9.
6. O'Neill AH, Gagnaniello C, Lai LT. Natural history of incidental colloid cysts of the third ventricle: A systematic review. J Clin Neurosci 2018;53:122-6.
7. de Witt Hamer PC, Versteegen MJ, de Haan RJ, Vandertop WP, Thomeer RT, Mooij JJ, et al. High risk of acute deterioration in patients harboring symptomatic colloid cysts of the third ventricle. J Neurosurg 2002;96:1041-5.
8. Hohenstein C, Herdtle S. Unexpected death from a colloid cyst. Int J Emerg Med 2010;3:65-6.
9. Shaktawat SS, Salman WD, Twajj Z, Al-Dawoud A. Unexpected death after headache due to a colloid cyst of the third ventricle. World J Surg Oncol 2006;4:47.
10. Kava MP, Tullu MS, Deshmukh CT, Shenoy A. Colloid cyst of the third ventricle: A cause of sudden death in a child. Indian J Cancer 2003;40:31-3.
11. Ryder JW, Kleinschmidt-DeMasters BK, Keller TS. Sudden deterioration and death in patients with benign tumors of the third ventricle area. J Neurosurg 1986;64:216-23.
12. Ogbodo E, Kaliaperumal C, Bermingham N, O'Sullivan M. Spontaneous haemorrhage and rupture of third ventricular colloid cyst. BMJ Case Rep 2012;2012:bcr2012006863.
13. Agrawal A, Santhi V, Umamaheswara RV. Giant colloid cyst of the third ventricle: Challenges in management. Chin Neurosurg J 2016;2:11.
14. Waggenspack GA, Guinto FC. MR and CT of masses of the anterosuperior third ventricle. AJR Am J Roentgenol 1989;152:609-14.
15. Powell MP, Torrens MJ, Thomson JL, Horgan JG. Isodense colloid cysts of the third ventricle: A diagnostic and therapeutic problem resolved by ventriculoscopy. Neurosurgery 1983;13:234-7.
16. Pollock BE, Schreiner SA, Huston J. A theory on the natural history of colloid cysts of the third ventricle. Neurosurgery 2000;46:1077-83.
17. Beaumont TL, Limbrick DD, Rich KM, Wippold FJ, Dacey RG. Natural history of colloid cysts of the third ventricle. J Neurosurg 2016;125:1420-30.
18. Alford EN, Rotman LE, Shank CD, Agee BS, Markert JM. Independent validation of the colloid cyst risk score to predict symptoms and hydrocephalus in patients with colloid cysts of the third ventricle. World Neurosurg 2020;134:e747-53.
19. Alford EN, Rotman LE, Lepard JR, Agee BS, Markert JM. Interrater and intrarater reliability of the colloid cyst risk score. Neurosurgery 2020;86:E47-53.
20. Dandy WE. Benign tumors of the third ventricle. In: Thomas CC, editor. Diagnosis and Treatment. Baltimore, IL: Springfield; 1933.
21. Lara FG, Patino R, Hakim S. Treatment of tumors of the third ventricle: A new and simple technique. Surg Neurol 1975;3:323-5.
22. Bosch DA, Rähn T, Backlund EO. Treatment of colloid cysts of the third ventricle by stereotactic aspiration. Surg Neurol 1978;9:15-8.
23. Rajshekhkar V. Rate of recurrence following stereotactic aspiration

- of colloid cysts of the third ventricle. *Stereotact Funct Neurosurg* 2012;90:37-44.
24. Mathiesen T, Grane P, Lindquist C, von Holst H. High recurrence rate following aspiration of colloid cysts in the third ventricle. *J Neurosurg* 1993;78:748-52.
 25. Kondziolka D, Lunsford LD. Microsurgical resection of colloid cysts using a stereotactic transventricular approach. *Surg Neurol* 1996;46:485-92.
 26. Kapu R, Symss NP, Pande A, Vasudevan MC, Ramamurthi R. Management of pediatric colloid cysts of anterior third ventricle: A review of five cases. *J Pediatr Neurosci* 2012;7:90-5.
 27. Hadjipanayis CG, Schuette AJ, Boullis N, Hao C, Barrow DL, Teo C. Full scope of options. *Neurosurgery* 2010;67:197-204.
 28. Vaish M, Patir R, Prasad R, Agrawal A. Single port microsurgical technique for excision of third ventricular colloid cysts. *Asian J Neurosurg* 2014;9:189-92.
 29. Yadav YR, Yadav S, Sherekar S, Parihar V. A new minimally invasive tubular brain retractor system for surgery of deep intracerebral hematoma. *Neurol India* 2011;59:74-7.
 30. Yasargil MG. Transchoroidal approach to the third ventricle: An anatomic study of the choroidal fissure and its clinical application. *Neurosurgery* 1998;42:1218-9.
 31. Wen HT, Rhoton AL, de Oliveira E. Transchoroidal approach to the third ventricle: An anatomic study of the choroidal fissure and its clinical application. *Neurosurgery* 1998;42:1205-17; discussion 1217-9.
 32. Deopujari C, Mohanty C. Anatomic variations of the fornix and its clinical implications. *Neurol India* 2016;64:947.
 33. Türe U, Yaşargil MG, Al-Mefty O. The transcallosal-transforaminal approach to the third ventricle with regard to the venous variations in this region. *J Neurosurg* 1997;87:706-15.
 34. Desai KI, Nadkarni TD, Muzumdar DP, Goel AH. Surgical management of colloid cyst of the third ventricle—a study of 105 cases. *Surg Neurol* 2002;57:295-302.
 35. Esposito V, di Russo P, del Maestro M, Ciavarrò M, Vangelista T, de Angelis M, *et al.* The interhemispheric transgenual approach for microsurgical removal of third ventricle colloid cysts. Technical note. *World Neurosurg* 2020;142:197-205.
 36. Fontenot P, Sandberg D. Rapid Recurrence of a Colloid Cyst after Endoscopic Resection. *Austin J Surg* 2014;1:1033.
 37. Aggleton JP, McMackin D, Carpenter K, Hornak J, Kapur N, Halpin S, *et al.* Differential cognitive effects of colloid cysts in the third ventricle that spare or compromise the fornix. *Brain* 2000;123:800-15.
 38. Hodges JR, Carpenter K. Anterograde amnesia with fornix damage following removal of IIIrd ventricle colloid cyst. *J Neurol Neurosurg Psychiatry* 1991;54:633-8.
 39. Symss N, Ramamurthi R, Kapu R, Rao S, Vasudevan M, Pande A, *et al.* Complication avoidance in transcallosal transforaminal approach to colloid cysts of the anterior third ventricle: An analysis of 80 cases. *Asian J Neurosurg* 2014;9:51.
 40. Nair S, Gopalakrishnan C, Menon G, Easwer H, Abraham M. Interhemispheric transcallosal transforaminal approach and its variants to colloid cyst of third ventricle: Technical issues based on a single institutional experience of 297 cases. *Asian J Neurosurg* 2016;11:292.
 41. Horn EM, Feiz-Erfan I, Bristol RE, Lekovic GP, Goslar PW, Smith KA, *et al.* Treatment options for third ventricular colloid cysts. *Neurosurgery* 2008;62 Suppl 3:613-20.
 42. Kehler U, Brunori A, Gliemroth J, Nowak G, Delitala A, Chiappetta F, *et al.* Twenty colloid cysts—comparison of endoscopic and microsurgical management. *Minim Invasive Neurosurg* 2001;44:121-7.
 43. Lewis AI, Crone KR, Taha J, van Loveren HR, Yeh HS, Tew JM. Surgical resection of third ventricle colloid cysts. Preliminary results comparing transcallosal microsurgery with endoscopy. *J Neurosurg* 1994;81:174-8.
 44. Levine NB, Miller MN, Crone KR. Endoscopic resection of colloid cysts: Indications, technique, and results during a 13-year period. *Minim Invasive Neurosurg* 2007;50:313-7.
 45. Grondin RT, Hader W, MacRae ME, Hamilton MG. Endoscopic versus microsurgical resection of third ventricle colloid cysts. *Can J Neurol Sci* 2007;34:197-207.
 46. Souweidane MM. Endoscopic surgery for intraventricular brain tumors in patients without hydrocephalus. *Neurosurgery* 2005;57 Suppl 4:312-8; discussion 312-8.
 47. Rangel-Castilla L, Chen F, Choi L, Clark JC, Nakaji P. Endoscopic approach to colloid cyst: What is the optimal entry point and trajectory? *J Neurosurg* 2014;121:790-6.
 48. Sharif S, Shaikh MY, Ali SM. Novel tool for minimally invasive Brain surgery—syringe port system. *World Neurosurg* 2019;131:339-45.
 49. McLaughlin N, Prevedello DM, Engh J, Kelly DF, Kassam AB. Endoneurosurgical resection of intraventricular and intraparenchymal lesions using the port technique. *World Neurosurg* 2013;79 Suppl 2:S18.e1-8.
 50. Chandra PS, Suri A, Rajender K, Sharma B, Mahapatra A, Mishra S. Endoscopic management of third ventricular colloid cysts: Eight years' institutional experience and description of a new technique. *Neurol India* 2010;58:412.
 51. Iacoangeli M, di Somma LG, di Rienzo A, Alvaro L, Nasi D, Scerrati M. Combined endoscopic transforaminal-transchoroidal approach for the treatment of third ventricle colloid cysts: Technical note. *J Neurosurg* 2014;120:1471-6.
 52. Osorio JA, Clark AJ, Safaei M, Tate MC, Aghi MK, Parsa A, *et al.* Intraoperative conversion from endoscopic to open transcortical-transventricular removal of colloid cysts as a salvage procedure. *Cureus* 2015;7:e247.
 53. Boogaarts HD, Decq P, Grotenhuis JA, Le Guérinel C, Nseir R, Jarraya B, *et al.* Long-term results of the neuroendoscopic management of colloid cysts of the third ventricle: A series of 90 cases. *Neurosurgery* 2011;68:179-87.
 54. Hoffman CE, Savage NJ, Souweidane MM. The significance of cyst remnants after endoscopic colloid cyst resection: A retrospective clinical case series. *Neurosurgery* 2013;73:233-7.
 55. Souweidane MM. Endoscopic surgery for intraventricular brain tumors in patients without hydrocephalus. *Neurosurgery* 2008;62 Suppl 6:1042-8.
 56. Lara-Reyna JJ, Uribe-Cardenas R, Perera I, Szerlip N, Giamouriadis A, Savage N, *et al.* Endoscopic removal of recurrent colloid cysts. *J Neurosurg* 2020;132:1636-41.
 57. Sethi A, Cavalcante D, Ormond DR. Endoscopic versus microscopic transcallosal excision of colloid cysts: A systematic review in the era of complete endoscopic excision. *World Neurosurg* 2019;132:e53-8.
 58. Sheikh AB, Mendelson ZS, Liu JK. Endoscopic versus microsurgical resection of colloid cysts: A systematic review and meta-analysis of

- 1278 patients. *World Neurosurg* 2014;82:1187-97.
59. Connolly ID, Johnson E, Lamsam L, Veeravagu A, Ratliff J, Li G. Microsurgical vs. Endoscopic excision of colloid cysts: An analysis of complications and costs using a longitudinal administrative database. *Front Neurol* 2017;8:259.
60. Macdonald RL, Humphreys RP, Rutka JT, Kestle JR. Colloid cysts in children. *Pediatr Neurosurg* 1994;20:169-77.
61. Vazhayil V, Sadashiva N, Nayak N, Prabhuraj AR, Shukla D, Somanna S. Surgical management of colloid cysts in children:

Experience at a tertiary care center. *Childs Nerv Syst* 2018;34:1215-20.

How to cite this article: Deopujari CE, Bhagwat AA, Karmarkar VS. Colloid Cysts of the Third Ventricle: A Review of Literature with Personal Experience. *Bombay Hosp J* 2021;63(1):11-20.

Source of support: Nil, **Conflicts of interest:** None

This work is licensed under a Creative Commons Attribution 4.0 International License. The images or other third party material in this article are included in the article's Creative Commons license, unless indicated otherwise in the credit line; if the material is not included under the Creative Commons license, users will need to obtain permission from the license holder to reproduce the material. To view a copy of this license, visit <http://creativecommons.org/licenses/by/4.0/> © Deopujari CE, Bhagwat AA, Karmarkar VS. 2021.