

## A Case of Scleral Tear with Expulsion of Lens and Uveal Prolapse with Vitreous Hemorrhage

### ABSTRACT

Open globe injuries are a major cause of blindness. Globe rupture injuries usually have a poor visual outcome. They are more common in males and are seen in the age group of 30-50 years.<sup>[1]</sup> Location of scleral tears is most commonly in the superonasal quadrant.<sup>[2,3]</sup> We report a case of scleral tear with uveal prolapse and crystalline lens expulsion where we were successful to achieve 6/18 vision after two surgeries, in an eye which would have otherwise become blind.

**Key words:** Globe rupture, Ocular injuries, Ocular trauma, Scleral fixated intraocular lens IOL, Scleral tear repair

### INTRODUCTION

Ocular trauma is the most important cause for unilateral vision loss and can be classified as open globe or closed globe injuries where the former refers to full thickness wounds. Open globe injuries maybe secondary to blunt trauma or lacerations and can be further subdivided into penetrating injuries, perforating injuries and intraocular foreign bodies. Repair of a corneo scleral tear is an ocular emergency and should be done at the earliest to decrease the chances of endophthalmitis and to restore the normal structural and functional anatomy of the eye. It is extremely important to assess the severity of the damage before exploring the wound. timely intervention and meticulous evaluations can salvage vision in compromised eyes.

### CASE REPORT

A 45-year-old male came with complaints of pain, sudden loss of vision, and bleeding from left eye after sustaining trauma due to bamboo stick to the left eye 3 h back. He visited a local doctor who prescribed systemic painkillers and antibiotic eye drops and referred him to a higher center. Patient gives no history of any previous ocular surgery or any systemic illness.

Local examination showed visual acuity of 6/12 in the right eye and PL present with faulty PR in the right eye. Intraocular pressure (IOP) was 14 mm of Hg in the right eye and in the left eye IOP was not recorded due to hypotony.

On slit-lamp examination, the left eye showed lid edema, ecchymosis, chemosis, and a contused lacerated wound of 2 cm in length and ½ cm deep below the brow. Subconjunctival peribulbar hematoma with ill-defined borders and a full-thickness conjunctival and scleral tear was seen nasally 10 mm in length from 6 to 11 o'clock with uveal prolapse. Corneal shape was dysmorphic and sheen was absent. There was a full chamber hyphema and a blood

Gauri Kishor Badhe, Manali Prashant Deosthali

*Department of Ophthalmology, Pravara Institute of Medical Sciences, Loni, Maharashtra, India*

#### Corresponding Author:

Gauri Kishor Badhe, Department of Ophthalmology, Pravara Institute of Medical Sciences, Loni, Maharashtra, India.

E-mail: prashantdeosthali@gmail.com

clot settled inferiorly. Iris, pupil, and lens details were not appreciated due to hyphema. The right eye was normal.

Fundus Examination – Normal in the right eye and was not possible due to hyphema in the left eye.

Routine hematological investigations and chest X-ray were normal. X-ray orbit showed that no radiopaque shadow suggestive of any intraocular FB was seen.

#### Surgical procedure

Scleral tear was explored and was seen to extend from 11 '0' clock to 7 '0' clock nasally with iris prolapse. Lens was auto expelled [Figure 1] and iris was abscised nasally. Scleral tear sutured with eight interrupted sutures using 8'0' Vicryl. Conjunctival tear sutured with three interrupted sutures using 8'0' Vicryl [Figure 2]. Cryo applications were done along the posterior edge of the sutured scleral tear from 11 '0' clock to 7 '0' clock with 1 mm on either side of tear ends [Figure 3]. The clot in ant. chamber gradually got absorbed. The fundus could not be seen due to vitreous hemorrhage. Vision was perception of light with projection of rays in all quadrants present and surgical aphakia was noted [Figure 4]. At the end of 6 weeks, the B-scan was done and vitreous hemorrhage was noted and the retina was well attached [Figure 5]. The ocular tension was 16 mm of Hg

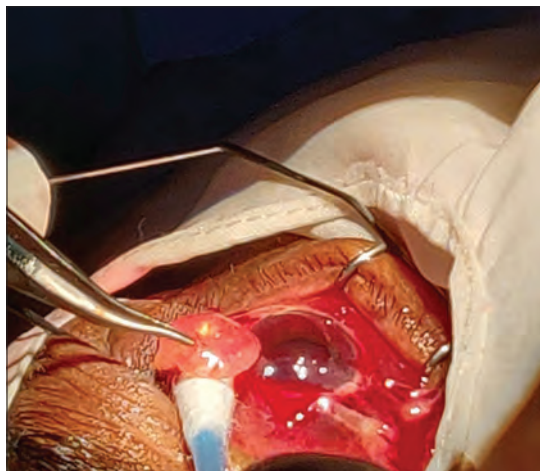


Figure 1: Auto expulsion of lens

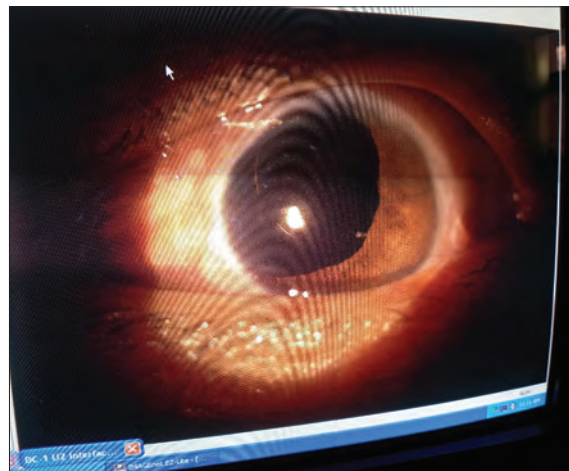


Figure 4: Surgical Aphakia

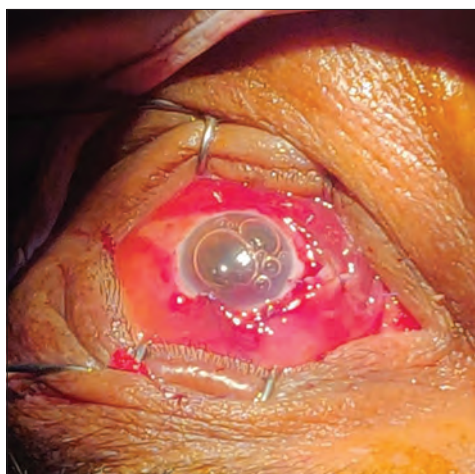


Figure 2: Scleral tear repair with surgical aphakia

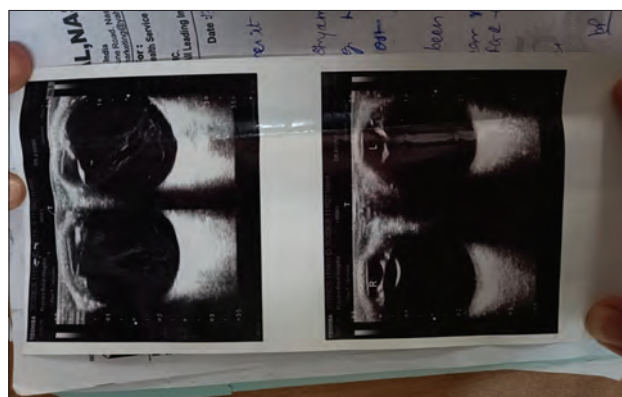


Figure 5: Bscan showing Vitreous hemorrhage

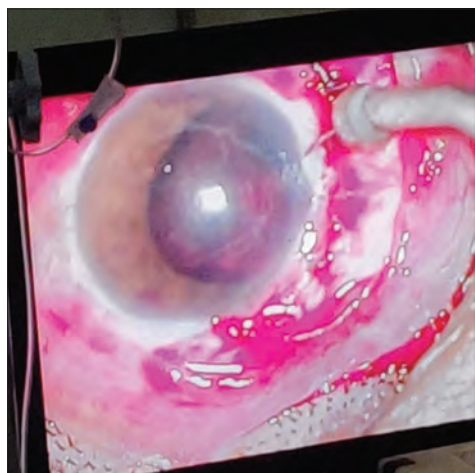


Figure 3: Cryoapplication

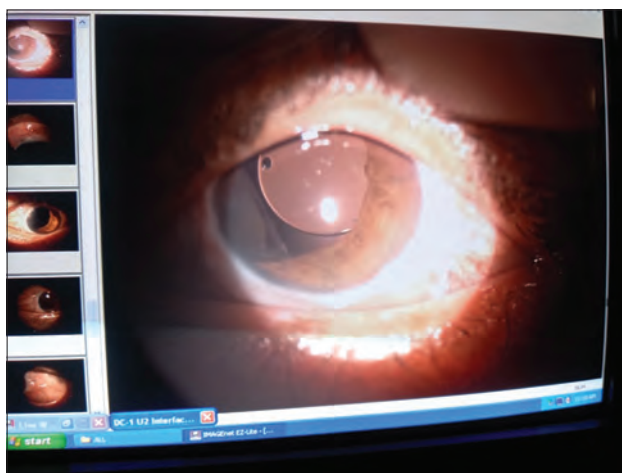

Figure 6: SFIOL in situ

on non-contact tonometer [Figure 6]. The left eye vitrectomy and secondary SFIOL implantation by Yamane's technique were done under LA 2 months later. Vision in L/E improved to

finger counting 1 m on day 1, finger counting at 3 meters on the 3<sup>rd</sup> day, and after 2 weeks to 6/60. At the end of 1 month, the best-corrected visual acuity in the left eye was 6/18.

## DISCUSSION

Globe rupture is a grievous condition where the integrity of the eye is disrupted by blunt or penetrating trauma, usually resulting from a full-thickness injury to the cornea or sclera.<sup>[3,4]</sup> Early management without unnecessary interventions such as B-scan ultrasonography and IOP estimation at the primary stage repair will avoid intraocular structural damage.<sup>[5]</sup>

The second stage surgery should be done after all signs of inflammation have quieted. The idea behind the Yamane technique is to externalize the haptics of a three-piece intraocular lens (IOL) using thin-walled 30- or 27-gauge needles through two transconjunctival sclerotomies. The flanged intrascleral IOL fixation using the double-needle technique first described by Dr. Shin Yamane involves some challenging steps.<sup>[6]</sup> Inserting the trailing haptic into the needle lumen is technically difficult because it requires the surgeon to use their left hand. The haptics of the IOL are carefully laced into the lumen of the needles using intraocular forceps.<sup>[7]</sup>

Cryo applications done along the posterior edge of the sutured scleral tear from 11 '0' clock to 7 '0' clock with 1 mm on either side of tear ends leads to aseptic inflammation and causes an adhesive scar around the tear.

## DECLARATION OF PATIENT CONSENT

The authors certify that they have obtained patient consent forms. In the form, the patient(s) has/have given his/her/their consent for his/her/their images and other information to be published in the journal. The patients understand that their names and initials will not be disclosed and due efforts will be made to conceal their identity, but anonymity cannot be guaranteed.

## CONCLUSION

A scleral tear is an ophthalmic emergency which usually has a poor visual outcome. Immediate primary repair can not only help in maintaining the structural and functional integrity of the eye but also helps in giving confidence and in turn a better life to the person who could have otherwise gone blind. A secondary intervention restores vision and gives livelihood and a normal appearance and function to the eye.

## REFERENCES

1. Rahman I, Maino A, Davadson D, Leatherbarrow B. Open globe injuries, factors predictive of visual outcome. *Eye* 2006;20:1336-44.
2. Agarwal R, Wei HS. Predictive factors for final outcome of severely traumatised eyes with no light perception. *BMC Ophthalmol* 2012;12:16.
3. Agaral R, Ho SW, Teoh S. Pre-operative variables affecting final visual outcome with a review of ocular trauma classification for posterior open globe injuries. *Indian J Ophthalmol* 2013;61:541-5.
4. Soni NG, Bauza AM, Son JH. Open globe ocular trauma: functional outcome of eyes with no light perception. *Retina* 2013;33:380-6.
5. Kuhn F, Morris R. A standardised classification of ocular trauma. *Ophthalmology* 1996;103:240-3.
6. Pieramici DJ. Ocular Trauma Principles and Practice Kuhn - A standardised classification of ocular trauma. *Ophthalmology* 2002;103:440-3.
7. Essex RW, Yi Q, Charles PG, Allen PJ. Post-traumatic endophthalmitis. *Ophthalmology* 2004;111:2015-22.

**How to cite this article:** Badhe GK, Deosthali MP. A Case of Scleral Tear with Expulsion of Lens and Uveal Prolapse with Vitreous Hemorrhage. *Bombay Hosp J* 2021;63(2):72-74.

**Source of support:** Nil, **Conflicts of interest:** None

This work is licensed under a Creative Commons Attribution 4.0 International License. The images or other third party material in this article are included in the article's Creative Commons license, unless indicated otherwise in the credit line; if the material is not included under the Creative Commons license, users will need to obtain permission from the license holder to reproduce the material. To view a copy of this license, visit <http://creativecommons.org/licenses/by/4.0/> © Badhe GK, Deosthali MP. 2021.