

A Case Report of Bilateral Primary Optic Atrophy in Children: Osteopetrosis – An Uncommon Cause

ABSTRACT

A 16-year-old boy presenting to us with profound visual impairment, squinting, with abnormally wide skull, limping gait underwent thorough ophthalmic and systemic examination. He had bilateral optic atrophy and radiological features were suggestive of osteopetrosis, a very rare clinical syndrome characterized by failure of osteoclasts to resorb bone with defective bone modeling and remodeling leading to increased skeletal fragility. The boy had significant narrowing of bilateral optic canals leading to compressive optic neuropathy. In children with abnormal skeletal features with bilateral optic atrophy, rare syndromes such as fibrous dysplasia, craniosynostosis, and osteopetrosis must be considered. Timely awareness about the condition could possibly guide the clinician to reach a proper diagnosis and take appropriate measures related to prevention of optic atrophy. There have been several case reports of early optic nerve decompression resulting in reversal of deterioration of vision. Our case report discusses osteopetrosis and also throws light on efficacy of optic nerve decompression in osteopetrosis with the aid of literature available so far.

Key words: Osteopetrosis, Primary optic atrophy, Optic canal decompression

Key Messages: Osteopetrosis is an infrequent cause of bilateral compressive optic neuropathy characteristic facial features with relevant history and imaging clinches the diagnosis.

CASE HISTORY

A 16-year-old boy presented to our outpatient department with a history of gradual painless diminution of vision both eyes (left eye more affected than right eye) over a period of several years. He also gave a history of constant outward squinting of the left eye from the past few years.

There was no history of pain, redness, watering, floaters, photopsia, ocular or head trauma, or prior ocular surgery. He reported nil systemic illness, no chronic drug therapy. There were no symptoms of raised intracranial tension.

There was a history of frequent fractures in the past with minimal trauma involving the right leg. Detailed family history revealed multiple fractures with trivial trauma in elder sister out of total seven siblings.

The boy was of short stature, poorly built, poorly nourished with the right leg deformity, limping gait, and scoliosis. He had a broad skull, frontal bossing, and a parrot beak nose [Figures 1 and 2]. The ophthalmic examination findings were as follows: Vision in the right eye was 6/60, N 36 and left eye was counting fingers at 2 feet. Pupillary examination showed sluggish reaction to light in both eyes, no relative afferent pupillary defect, and no anisocoria. On color vision assessment with Ishihara's chart and pseudoisochromatic chart, he could identify only the demo plates in both eyes. Confrontation test showed constricted fields in both eyes. Objective cycloplegic refraction was right eye -1.00DC at 90 and left eye $+1.00\text{DS}/-4.00\text{DC}$ at 100 with no

Akash Jeevan Jain, Harsha Sameer Pagad, Nita Umesh Shanbhag

Department of Ophthalmology, Dr D. Y. Patil Medical College and Hospital, Navi Mumbai, Maharashtra, India

Corresponding Author:

Harsha Sameer Pagad, Department of Ophthalmology, Dr D. Y. Patil Medical College and Hospital, Navi Mumbai, Maharashtra, India.

E-mail: harushsam@yahoo.co.in

subjective improvement in vision with correction. Fundus examination showed optic discs of normal size, circular, 0.3:1 cup-disc ratio temporal pallor with distinct margin in both eyes [Figure 3]. There was no peripapillary gliosis. Squint evaluation revealed left constant exotropia with no A or V pattern. Extraocular movements were full and free in all gazes [Figure 4].

A diagnosis of primary optic atrophy was made based on the clinical findings and with the skeletal system involved, we decided to investigate further with computed tomography (CT) scan of brain and orbit. CT scan (brain with orbit) showed dense sclerosis of the skull and craniofacial bones with loss of corticomedullary differentiation, hypoplasia of the paranasal sinuses, crowding at the orbital apex with narrowing of optic canals (diameter both eyes: $<3\text{ mm}$), and significant narrowing of bilateral internal auditory canals [Figures 5 and 6]. These CT findings were suggestive of osteopetrosis.

Normal average transverse diameter of the optic canal is 3.57 ± 0.61 mm and the longitudinal diameter is 4.82 ± 0.38 mm.^[1] Further, evaluation with magnetic resonance imaging (MRI) was needed to evaluate for optic nerve sheath compression, the patient was not willing for the same. Perimetry was tried with size V stimuli was not possible

In view of above radiological findings, recurrent fractures, primary optic atrophy, and bilateral narrow optic canals, a diagnosis of compressive optic neuropathy secondary to compression of optic nerve due to abnormal bone formation at the optic canals due to underlying osteopetrosis was made. The differentials of primary optic atrophy in children such as hereditary, toxic, nutritional, and pituitary tumors induced optic atrophy were considered while evaluating the patient.

The possibility of hereditary and toxic optic neuropathy was ruled out from the negative history obtained from the patient.

In view of diagnosis of osteopetrosis, the patient underwent thorough hematological assessment to rule out bone marrow involvement. Peripheral smear showed microcytic hypochromic anemia with anisopoikilocytosis. White blood cells and platelets were adequate and normal. The patient had no hepatosplenomegaly



Figure 1: Broad skull

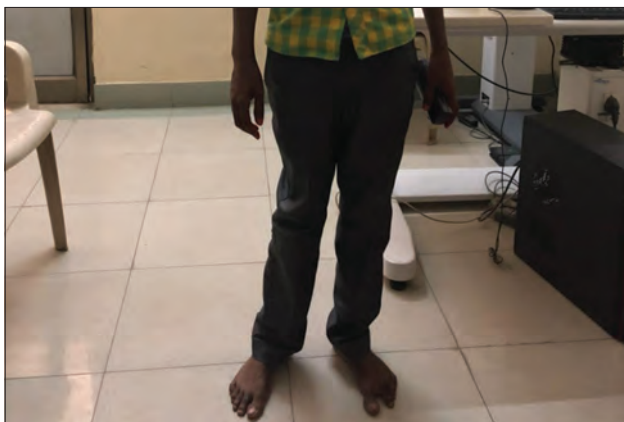

Figure 2: Short stature with leg deformity

on ultrasonography abdomen. There was no significant hearing loss on audiometry. He was also sent for a complete orthopedic evaluation. We did not advise visual evoked potential (VEP) as it would not help in any prognostication and further management. Further, evaluation with MRI brain with orbit was needed to evaluate for optic nerve sheath compression, the patient was not willing for the same and was lost to follow-up.

DISCUSSION

Osteopetrosis is caused by reduced activity of osteoclasts which results in defective remodeling of bone and increased bone density.^[2] The defect in bone turnover results in skeletal fragility despite increased bone mass, and it may also cause hematopoietic insufficiency, disturbed tooth eruption, nerve entrapment syndromes, and growth impairment. Sclerosis of bones and narrowing of bony foramina leads to compressive neuropathies. Typically osteopetrosis presents with fractures, short stature, and hypocalcemia, pancytopenia, and optic nerve compression and rarely hypogenitalism.^[3] There are three clinical groups of osteopetrosis, namely, infantile malignant autosomal recessive, intermediate autosomal recessive, and autosomal dominant type. The incidence of autosomal recessive osteopetrosis is 1 in 250,000 births and autosomal dominant osteopetrosis is 1 in 20,000 births.^[4] Our patient probably belonged to the intermediate autosomal recessive group as there was no history of parents affected with only one other sibling having similar phenotype with fractures. A detailed genetic testing would be conclusive. Investigations recommended are CT scan (brain, orbit), MRI (brain, orbit), radionuclide bone scan, genetic analysis, iliac crest bone biopsy, and skeletal survey. Ophthalmic manifestations in osteopetrosis include chorioretinal degeneration, nystagmus, strabismus, proptosis, and ptosis apart from optic atrophy.^[5] Sporadic ocular association of cataract has been reported. Chorioretinal degeneration may also be a significant cause of visual loss in patients with infantile malignant osteopetrosis, and this may explain lack of response to decompression surgery in some cases.^[5] An electroretinogram may be done to rule out same. The VEPs are the most useful way of monitoring optic nerve involvement. Bone marrow transplant (BMT) has been reported

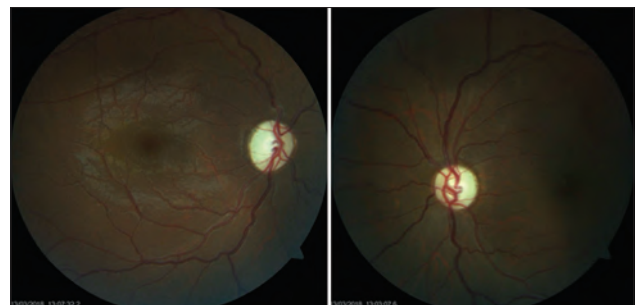


Figure 3: Fundus picture showing temporal pallor of disc with distinct margins in both eyes

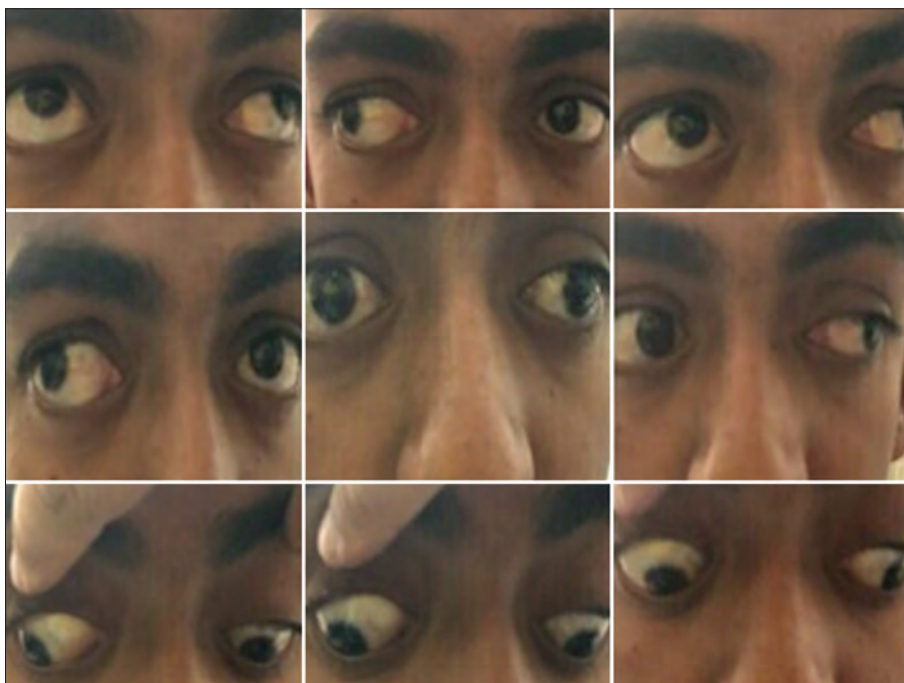

Figure 4: Left eye exotropia noted on 9-gaze photograph

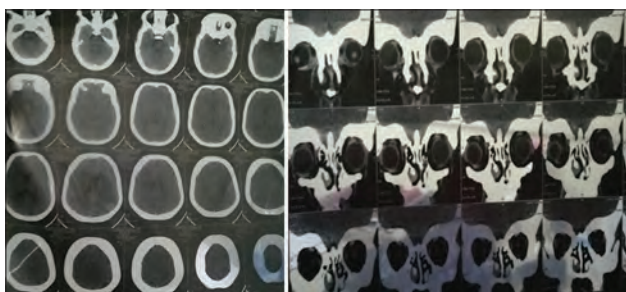


Figure 5: Computed tomography scan showing dense sclerosis of craniofacial bones on axial and coronal section

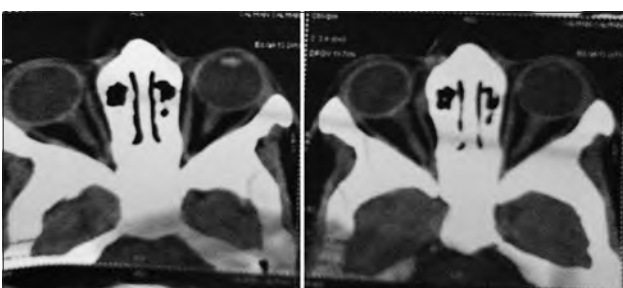


Figure 6: Computed tomography scan showing narrowing of optic canals on axial view

as a successful treatment option to widen the narrow optic canal in infantile osteopetrosis.^[6] Human leukocyte antigen-matched allogeneic hematopoietic stem cell transplantation (to provide the diseased bone with normal osteoclasts) is the only treatment

known to significantly alter the course of the disease in infantile osteopetrosis.^[7,8] In young children, BMT will preserve the existing vision but cannot reverse the damage that has occurred already. Optic canal decompression may be beneficial in some patients but not in others with chorioretinal degeneration. Optic canal decompression in the early stage of visual deterioration may reverse vision loss. It has been emphasized that optic nerve decompression should be wide and include not only unroofing of the bony canal but also drilling along both sides of the optic nerve as well as smoothing of the thick, irregular, and highly domed orbital roof by high-speed drilling to facilitate surgical exposure with minimal retraction of the frontal lobe.^[8]

The timing and efficacy of optic nerve decompression is debatable. Like in our patient will optic nerve decompression prevent further loss of vision in the good eye is highly confounding. There have been reports of complete reversal of visual deterioration by extensive optic nerve decompression which included unroofing the optic canal and also drilling away bone on both sidewalls of the optic nerve.^[9] Another report shares experience with six children suffering from osteopetrosis and severe visual loss where all six patients underwent bilateral microsurgical optic nerve decompression through a supraorbital craniotomy. Improvement in visual acuity occurred postoperatively in five patients, and none had complications.^[10]

CONCLUSION

In conclusion, ophthalmologist can play a pivotal role in the diagnosis of rare systemic conditions. When evaluating cases of

optic atrophy in young patients: Rare syndromes can be one of the causes. Timely awareness about the condition could possibly guide the clinician to take measures such as BMT or optic canal decompression related to the prevention of optic atrophy.

REFERENCES

1. Liu X, Zhou C, Zhang G, Lin Y, Li S. CT anatomic measurement of the optic canal and its clinical significance. *Zhonghua Er Bi Yan Hou Ke Za Zhi* 2000;35:275-7.
2. Steward CG. Neurological aspects of osteopetrosis. *Neuropathol Appl Neurobiol* 2003;29:87-97.
3. Gupta SP. Marble bone disease, osteopetrosis. *Indian J Ophthalmol* 1958;6:52-4.
4. Stark Z, Savarirayan R. Osteopetrosis. *Orphanet J Rare Dis* 2009;4:5.
5. Albert DM, Miller JW, Azar DT, Blodi BA. Osseous and musculoskeletal disorders. In: Albert and Jakobiec's Principles and Practice of Ophthalmology. 3rd ed., Vol. 4, Ch. 330. Philadelphia, PA, USA: Saunders, Elsevier; 2008. p. 4507-8.
6. Kerr NC, Wang WC, Mohadjer Y, Haik BG, Kaste SC, Horwitz EM. Reversal of optic canal stenosis in osteopetrosis after bone marrow transplant. *Am J Ophthalmol* 2000;130:370-2.
7. Gerritsen EJ, Vossen JM, Fasth A, Friedrich W, Morgan G, Padmos A, *et al.* Bone marrow transplantation for autosomal recessive osteopetrosis. A report from the working party on inborn errors of the European Bone Marrow transplantation group. *J Pediatr* 1994;125:896-902.
8. Solh H, Da Cunha AM, Giri N, Padmos A, Spence D, Clink H, *et al.* Bone marrow transplantation for infantile malignant osteopetrosis. *J Pediatr Hematol Oncol* 1995;17:350-5.
9. Hwang JM, Kim IO, Wang KC. Complete visual recovery in osteopetrosis by early optic nerve decompression. *Pediatr Neurosurg* 2000;33:328-32.
10. Al-Mefty O, Fox JL, Al-Rodhan N, Dew JH. Optic nerve decompression in osteopetrosis. *J Neurosurg* 1988;68:80-4.

How to cite this article: Jain AJ, Pagad HS, Shanbhag NU. A Case Report of Bilateral Primary Optic Atrophy in Children: Osteopetrosis – An Uncommon Cause. *Bombay Hosp J* 2021;63(2):79-82.

Source of support: Nil, **Conflicts of interest:** None

This work is licensed under a Creative Commons Attribution 4.0 International License. The images or other third party material in this article are included in the article's Creative Commons license, unless indicated otherwise in the credit line; if the material is not included under the Creative Commons license, users will need to obtain permission from the license holder to reproduce the material. To view a copy of this license, visit <http://creativecommons.org/licenses/by/4.0/> © Jain AJ, Pagad HS, Shanbhag NU. 2021.