

Rare Cause of Pain in Abdomen in Second Trimester Pregnancy

ABSTRACT

Scar dehiscence as a cause of pain in abdomen in second trimester is rare. It is usually seen in third trimester of pregnancy. We report an interesting case of 33-year-old women with post-myomectomy scar dehiscence in second trimester of pregnancy. She was admitted in emergency with acute pain in abdomen. We performed an emergency laparotomy which revealed a transverse uterine scar dehiscence from the old myomectomy site and an intact amniotic sac in the abdominal cavity. This case implies that the uterine dehiscence should be considered as a differential diagnosis in pregnant women presenting with acute abdominal pain even in early gestational age, as it can result in maternal as well as fetal mortality.

Key words: Acute abdomen, Post-myomectomy scar, Uterine scar dehiscence

INTRODUCTION

Uterine dehiscence in pregnancy is a rare life-threatening complication. It mainly occurs in third trimester of pregnancy or during labor, especially in previously scarred uterus. It is rarely seen during the second trimester. Uterine dehiscence is referred to the process of gradual myometrial rupture without disruption of overlying uterine serosa in a pre-existing scar. The fetus, placenta, and umbilical cord are within the uterine cavity.

CASE REPORT

A 33-year-old primigravida, at 22 weeks of gestation, presented in emergency with complaints of severe diffuse pain in abdomen. There were no other complaints.

She had a history of infertility for which she had undergone evaluation which showed multiple fibroids on ultrasonography, there were broad ligament of 2.6 × 5.7 cm size, posterior intramural fibroid of 2.3 × 1.5 cm size, and fundal fibroid of 2.3 × 5 cm in size. Laparoscopic myomectomy was done for the same 2 years back in which the incision after myomectomy was sutured with Vicryl no. 1 interrupted sutures in 2–3 layers and there was no evidence of entering the endometrial cavity while doing myomectomy. She had taken multiple trials of ovulation induction followed by hysteroscopy with cervical dilatation which was done in January 2019. She conceived with IUI in March 2019.

The patient was admitted. On examination, her blood pressure was 118/74 mmHg, pulse rate (PR) was 103/min, body temperature (T) was 37°C, respiratory rate was 25/min, and SpO₂ was 100%.

Per abdomen examination revealed generalized tenderness and a uterus corresponding to 22 weeks. Fetal cardiac activity was present. The speculum examination was also normal.

Firdousara Siddiqui¹, Varsha Pai Dhungat²

¹Department of Obstetrics and Gynecology, Bombay Hospital Institute of Medical Sciences, Mumbai, Maharashtra, India, ²Department of Obstetrics and Gynecology, Bombay Hospital, Mumbai, Maharashtra, India

Corresponding Author:

Dr. Firdousara Siddiqui, Department of Obstetrics and Gynecology, Bombay Hospital Institute of Medical Sciences, Mumbai, Maharashtra, India.
Phone: +91-9552010659. E-mail: firdousara12@gmail.com

There was no bleeding per vagina or hematuria.

Laboratory investigations were normal. Abdominal and pelvic ultrasound was done in emergency showed viable fetus with moderate hemoperitoneum.

In view of ultrasound findings, diagnostic laparoscopy was done. Laparoscopic visualization revealed gross hemoperitoneum of about 800 cc. Decision was then taken to do exploratory laparotomy which surprisingly showed amniotic sac bulging from uterine fundal wall and uterine scar dehiscence [Figures 1-3]. The fetus was then delivered which was dead at the time of operation.

She was discharged on post-operative day 5 in healthy condition.

DISCUSSION

Second trimester spontaneous myomectomy scar dehiscence is a very rare condition and can be fatal if not diagnosed and managed properly. The prevalence of uterine rupture over cesarean section scarring is about 1%,^[1] while rupture over non-scarred uterus is rare, occurring in 1/5700–1/20,000 pregnancies.^[2] An increase in the rate of uterine rupture,

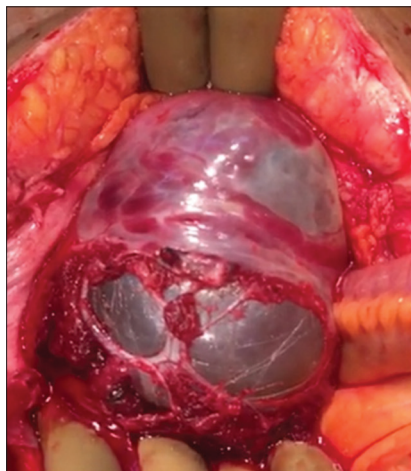


Figure 1: Whole sac coming out through uterine muscle layer

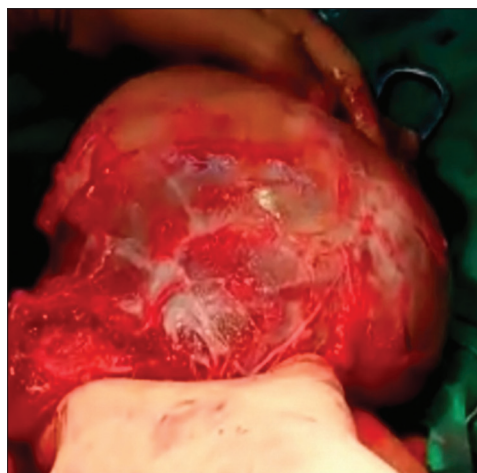


Figure 2: Amniotic membrane seen through dehiscence in the myometrium

particularly due to increase in cesarean sections and labor inductions, has been observed in recent decades.^[3]

Myomectomy for infertility has best outcome if done laparoscopically due to less post-operative adhesions and less recovery time. It is usually necessary to do cesarean section in next pregnancy due to risk of scar rupture during labor.

Myomectomy scars usually are at risk of dehiscence or rupture if surgery to conception duration is less than 3 months or induction done to terminate pregnancy in second trimester and induction at third trimester.^[4]

Spontaneous scar dehiscence rarely occurs^[5] in second trimester after an adequate time interval between myomectomy and conception. Most of the cases of scar dehiscence found during elective cesarean section without preceding clinical symptoms.

Uterine rupture was defined as the occurrence of clinical symptoms (abdominal pain, abnormal fetal heart rate pattern, acute loss of contractions, and vaginal blood loss) leading to an

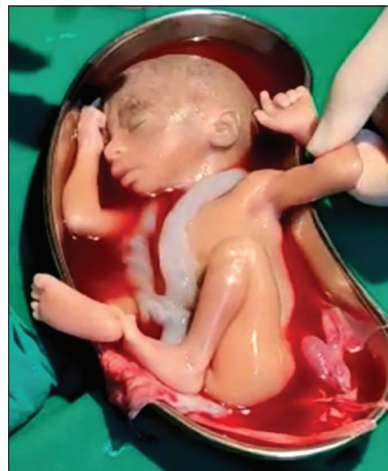

Figure 3: Abortus after expulsion through scar

emergency cesarean delivery, at which the presumed diagnosis of uterine rupture was confirmed or peripartum hysterectomy or laparotomy for uterine rupture after vaginal birth.

CONCLUSION

Scars of myomectomy are known to rupture. Second trimester pain in abdomen should be managed aggressively. Signs and symptoms of uterine rupture such as abnormal fetal heart rate pattern and abdominal pain should be taken seriously even in unscarred uterus. It is safer to do cesarean section in pregnant patient with myomectomy scar and in which endometrial cavity was open during procedure of myomectomy, though we can give trial of vaginal delivery considering all due risk and complication of uterine scar rupture.

ACKNOWLEDGMENT

We would like to express special thanks and gratitude to Dr. Suvarna Khadilkar, Professor and head of department ObGyn and Consultant Endocrinologist and Gynecologist, Bombay Hospital Institute of Medical Sciences and BH Medical Research Centre, for her guidance and support. Grateful for the precious tips.

REFERENCES

1. Hofmeyr GJ, Say L, Gülmezoglu AM. Systematic review: WHO systematic review of maternal mortality and morbidity: The prevalence of uterine rupture. *BJOG* 2005;112:1221-8.
2. Zwart JJ, Richters JM, Ory F, de Vries JI, Bloemenkamp KW, van Roosmalen J. Uterine rupture in the Netherlands: A nationwide population-based cohort study. *BJOG* 2009;116:1069-78; discussion 1078-80.
3. Al-Zirqi I, Stray-Pedersen B, Forsén L, Daltveit AK, Vangen S. Uterine rupture: Trends over 40 years. *BJOG* 2016;123:780-7.
4. Kiseli M, Artas H, Armagan F, Dogan Z. Spontaneous rupture

of uterus in midtrimester pregnancy due to increased uterine pressure with previous laparoscopic myomectomy. *Int J Fertil Steril* 2013;7:239-42.

5. Song SY, Yoo HJ, Kang BH, Ko YB, Lee KH, Lee M. Two pregnancy cases of uterine scar dehiscence after laparoscopic myomectomy. *Obstet Gynecol Sci* 2015;58:518-21.

How to cite this article: Siddiqui F, Dhungat VP. Rare Cause of Pain in Abdomen in Second Trimester Pregnancy. *Bombay Hosp J* 2021;63(2):83-85.

Source of support: Nil, **Conflicts of interest:** None

This work is licensed under a Creative Commons Attribution 4.0 International License. The images or other third party material in this article are included in the article's Creative Commons license, unless indicated otherwise in the credit line; if the material is not included under the Creative Commons license, users will need to obtain permission from the license holder to reproduce the material. To view a copy of this license, visit <http://creativecommons.org/licenses/by/4.0/> © Siddiqui F, Dhungat VP. 2021.